



ABO Sample Cases (Part II)

(Rev. 06.12.2024)

Disclaimer

- The following sample questions and answers were composed and vetted by a panel of experts in orthodontics and are intended to provide a guide of the types of cases and questions that make up the actual Scenario-based Clinical Examination.
- After the examination, trained examiners, who are all in-good-standing board certified orthodontists, will score the typed responses using rubrics as guides to their decision making.
- Rubrics help to create consistency in the decisions the examiners make while grading an examinees typed responses. The rubrics are not absolute, as there may be other acceptable answers that are not listed. However, no credits will be awarded for answers not included in the rubrics.

Disclaimer Cont.

- The ABO has developed multiple versions of the case-based scenario examination to be used during a test administration cycle. Although the set of cases and questions used on the different versions will not all be the same, all versions follow the same content framework as defined by the practice analysis study.
- Scores will be computed using psychometric equating procedures to ensure that all versions are of the same difficulty level.
- Review of these sample cases does not guarantee that a candidate will pass the examination.
- Examinee responses to exam questions will be typed out and should be in numbered list format (i.e., short and concise, no essay responses).

Sample Case #6

Sample Case #6

Opening Scenario:

A 10-year-old male patient presents with the chief complaint, “my dentist said I have a lot of crowding.”

Sample Case #6

Question 1

Classification

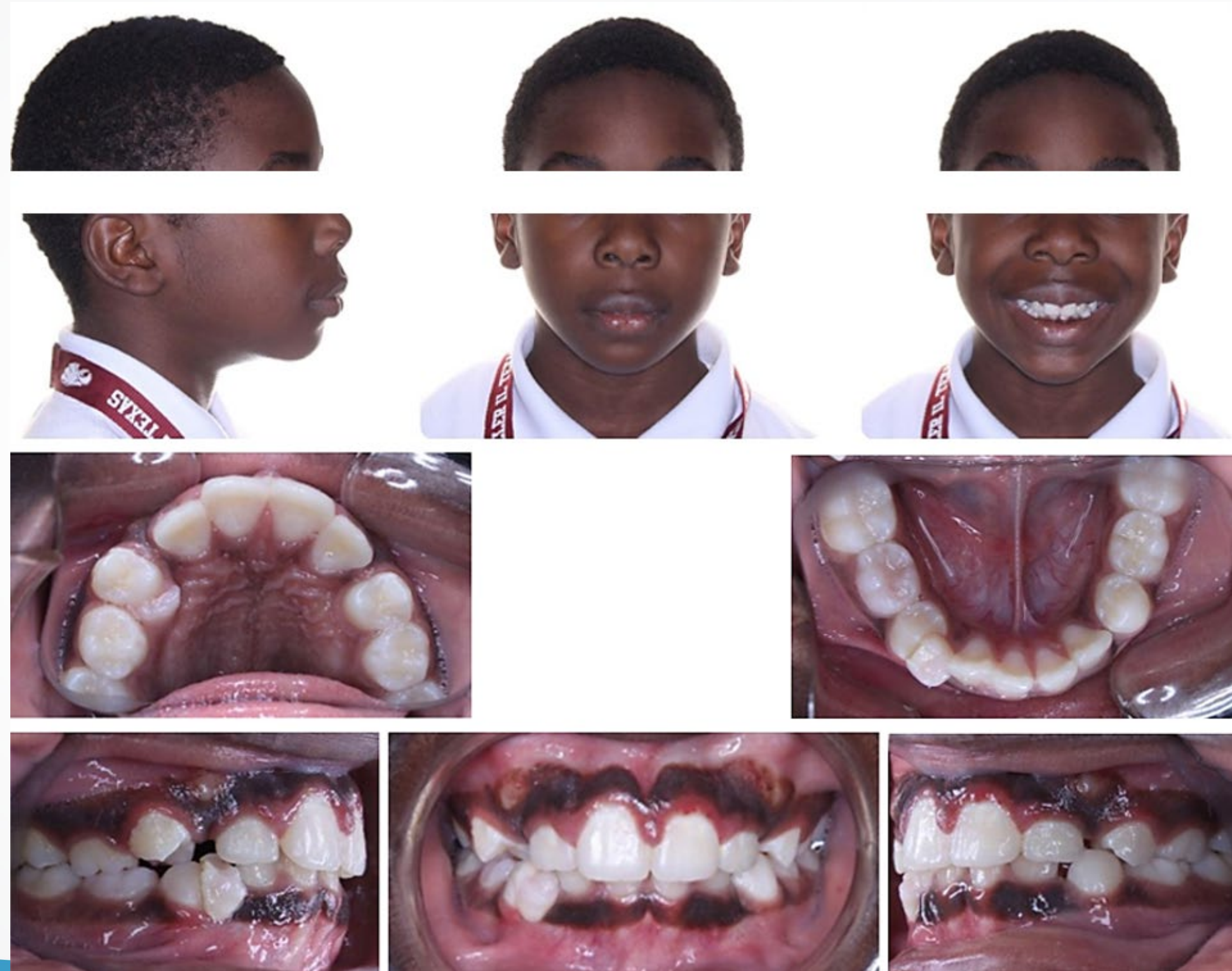
Domain 1: Data Gathering and Diagnosis

Prompt

Identify the skeletal findings. Please respond in numbered list format below.

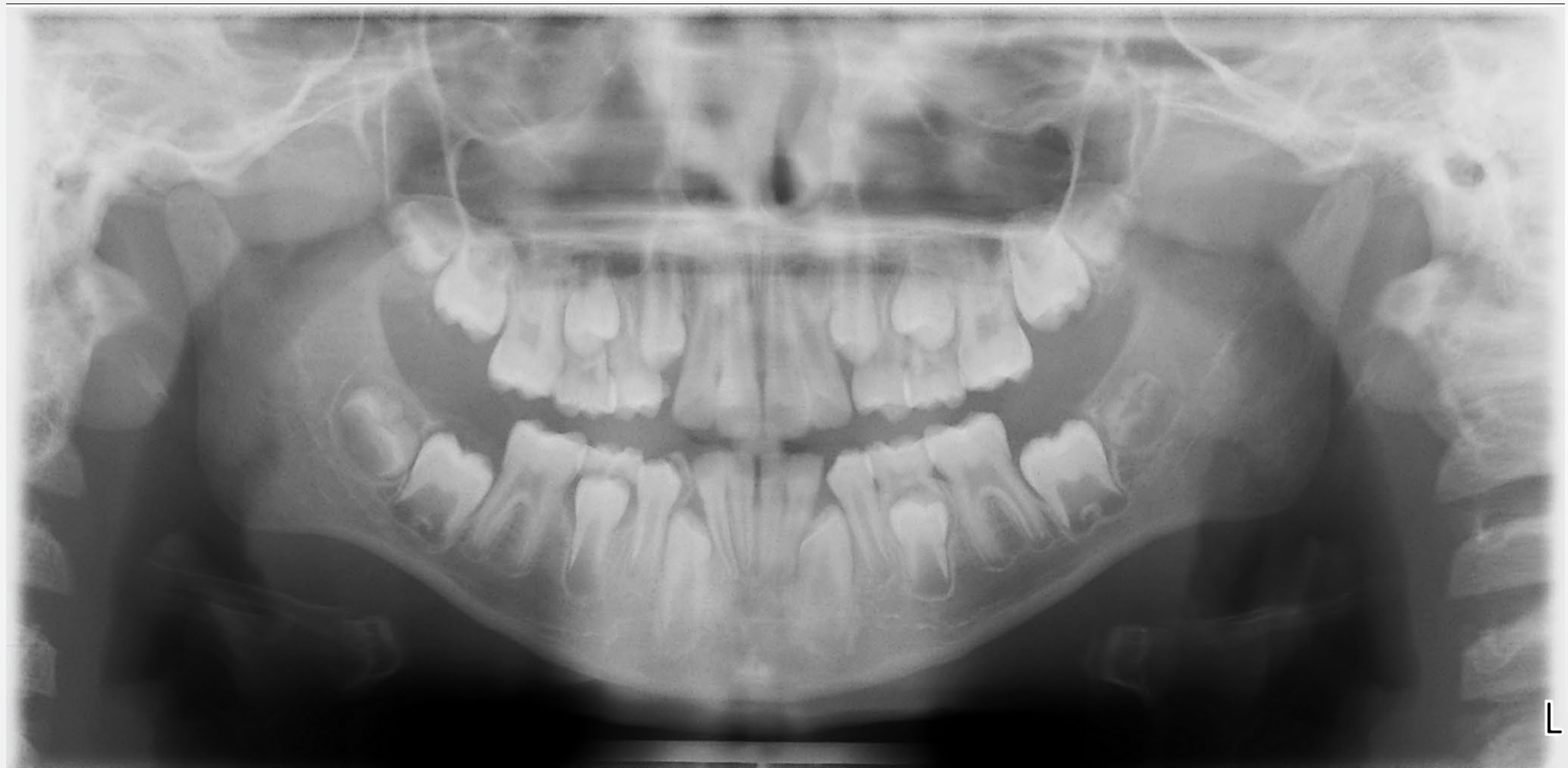Sample Case #6

Question 1



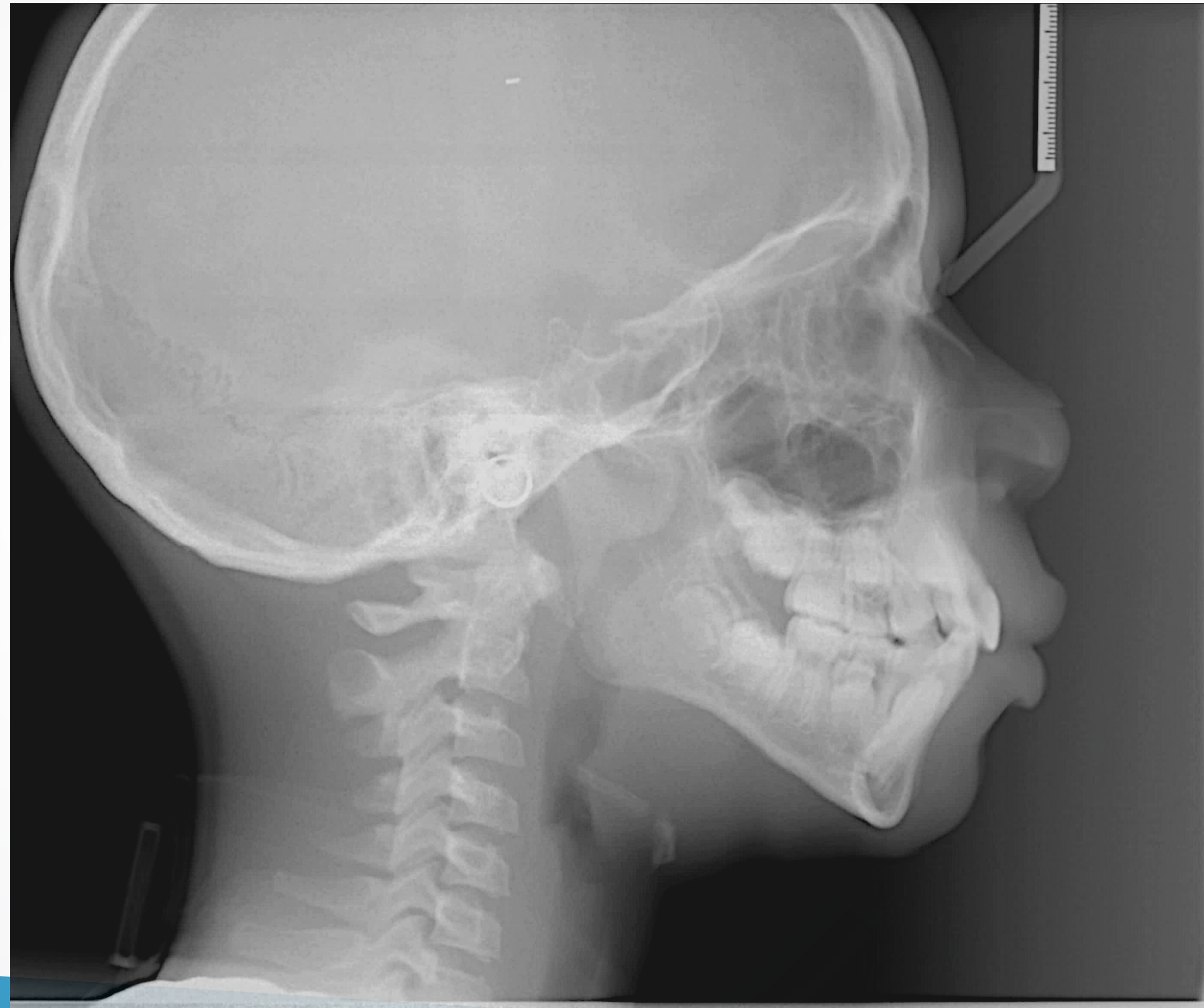Sample Case #6

Question 1



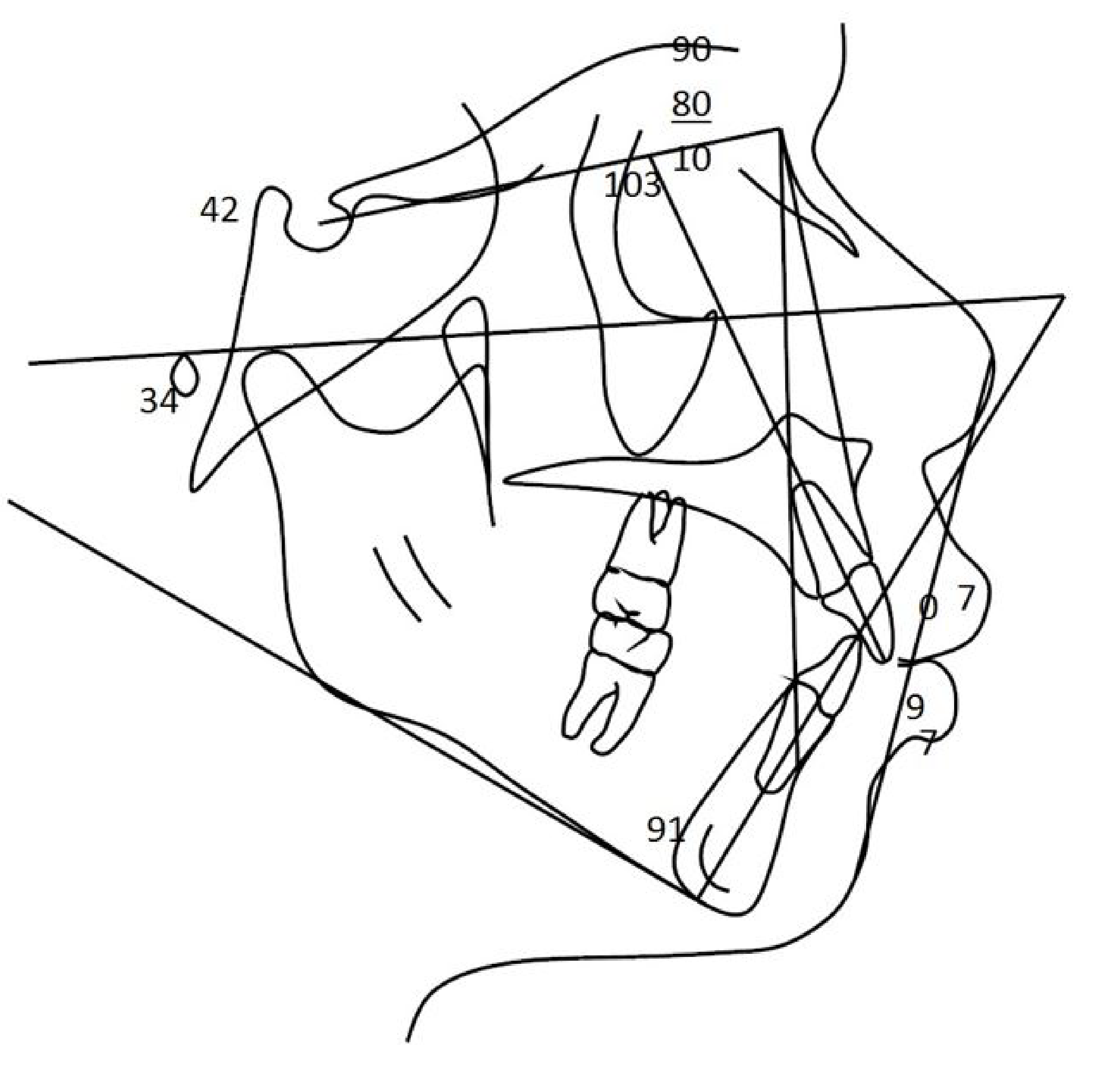
Sample Case #6

Question 1



Sample Case #6

Question 1



Sample Case #6

Question 1

Classification

Domain 1: Data Gathering and Diagnosis

Prompt

Identify the skeletal findings. Please respond in numbered list format below.

Sample Case #6

Question 1

Fully Proficient Model Response

The examinee's response must include four or more of the following:

1. Skeletal Class II
2. Protrusive maxilla
3. Retrusive mandible
4. Short ramus
5. Steep mandibular plane angle (accept hyperdivergent growth pattern)

Sample Case #6

Question 1

Borderline Proficient Model Response

The examinee's response must include three of the above.

Not Proficient Model Response

The examinee's response includes two or fewer of the above.

Sample Case #6

Question 2

Classification

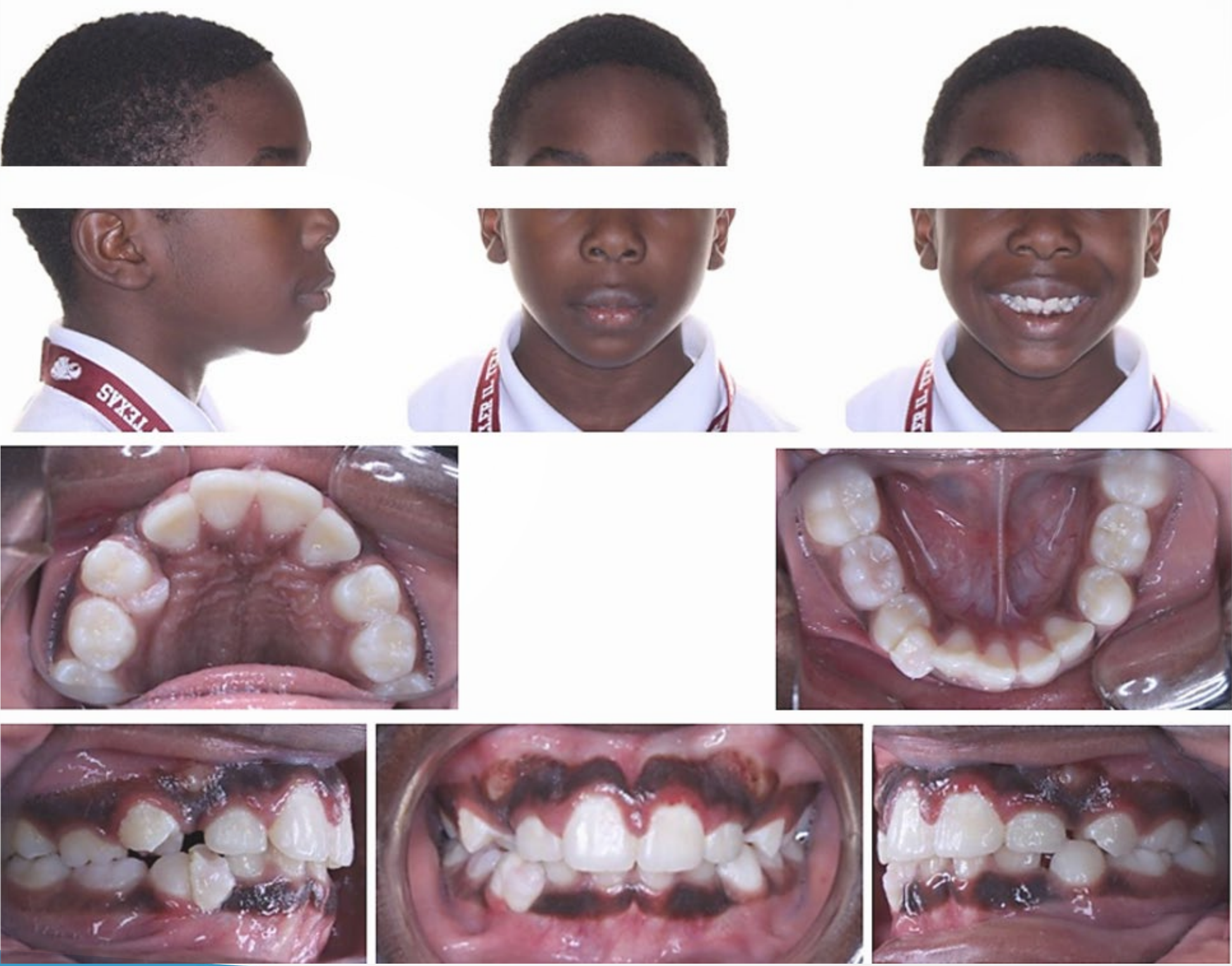
Domain 1: Data Gathering and Diagnosis

Prompt

Identify the dental findings. Please respond in numbered list format below.

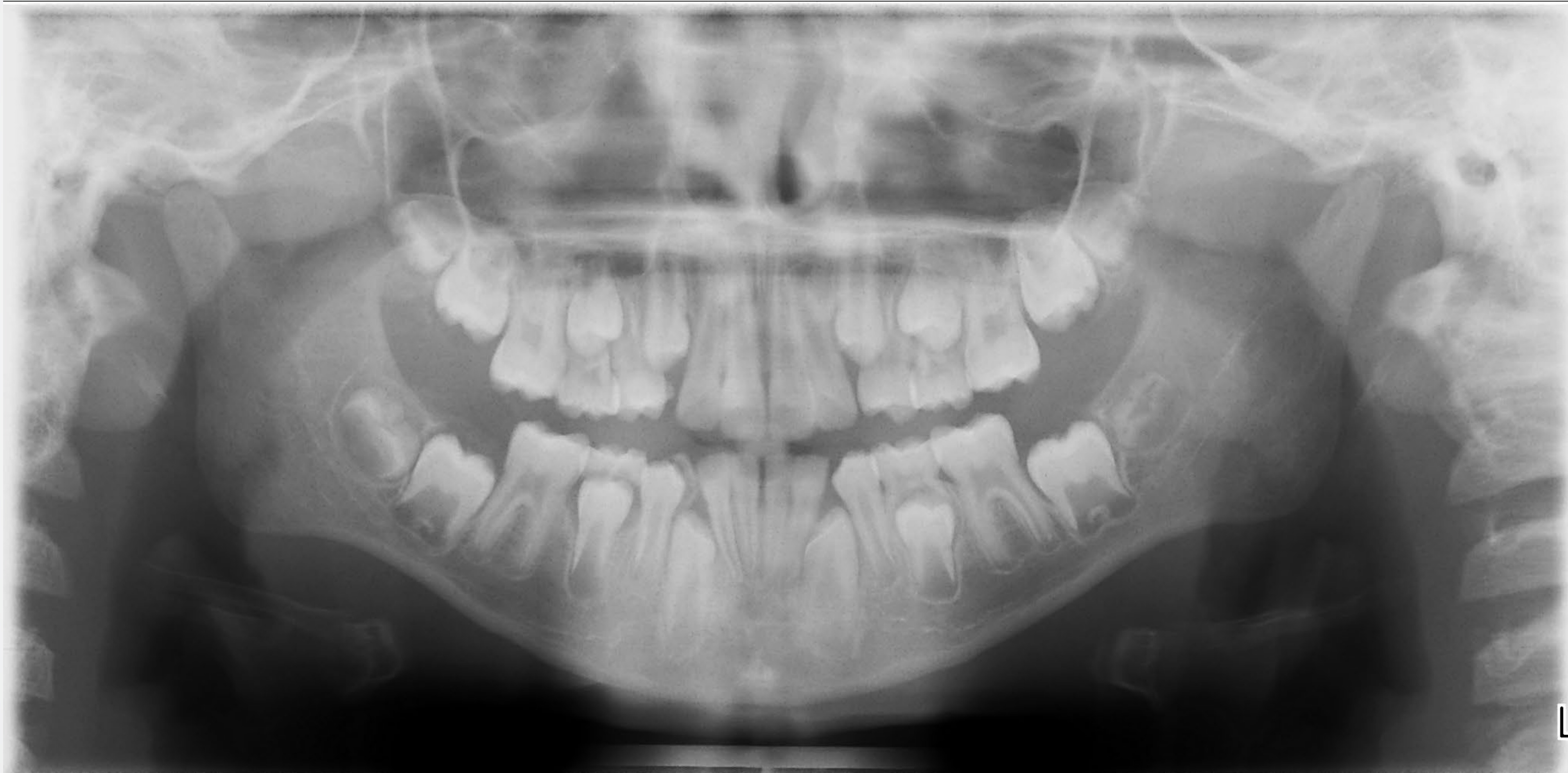Sample Case #6

Question 2



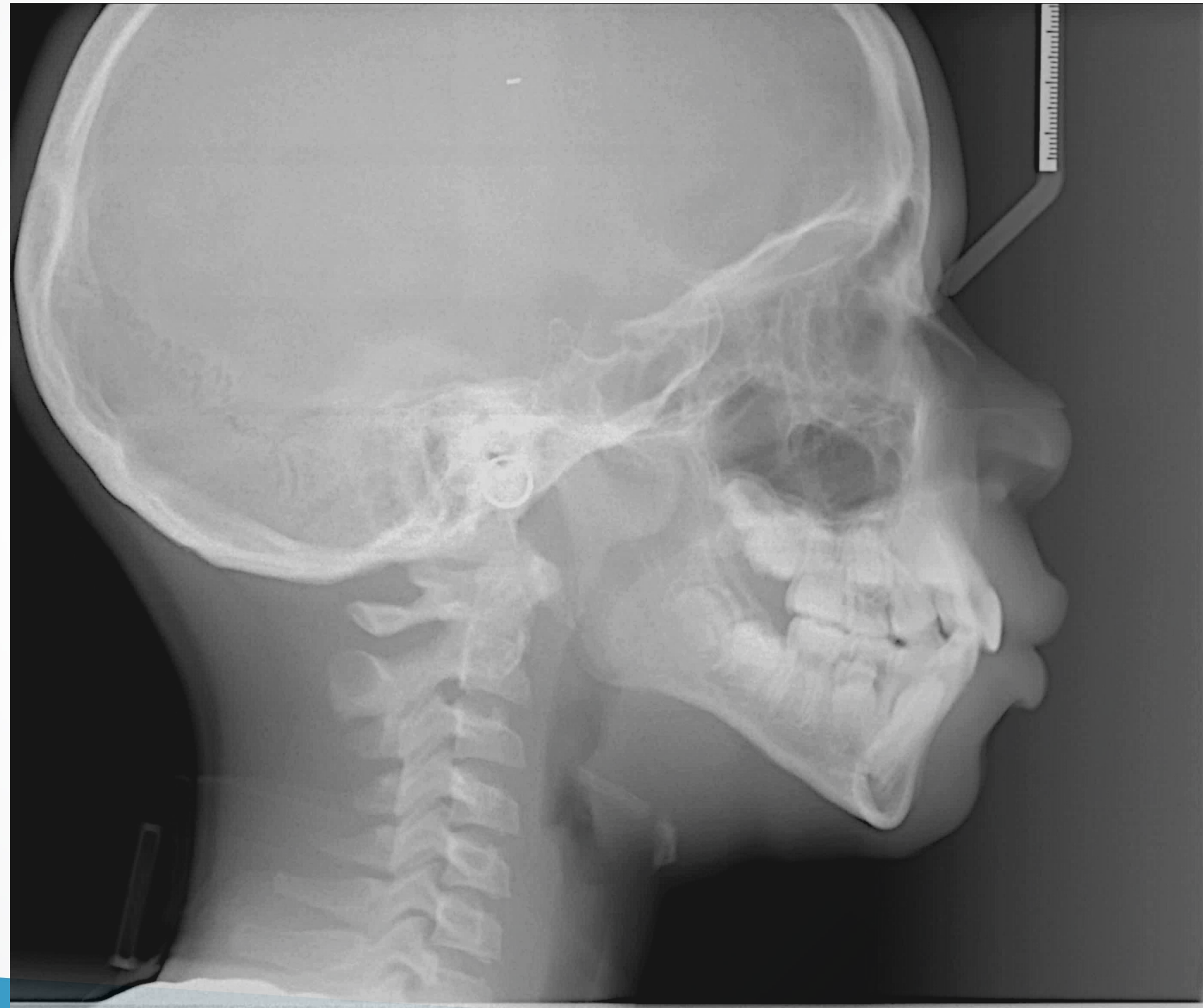Sample Case #6

Question 2



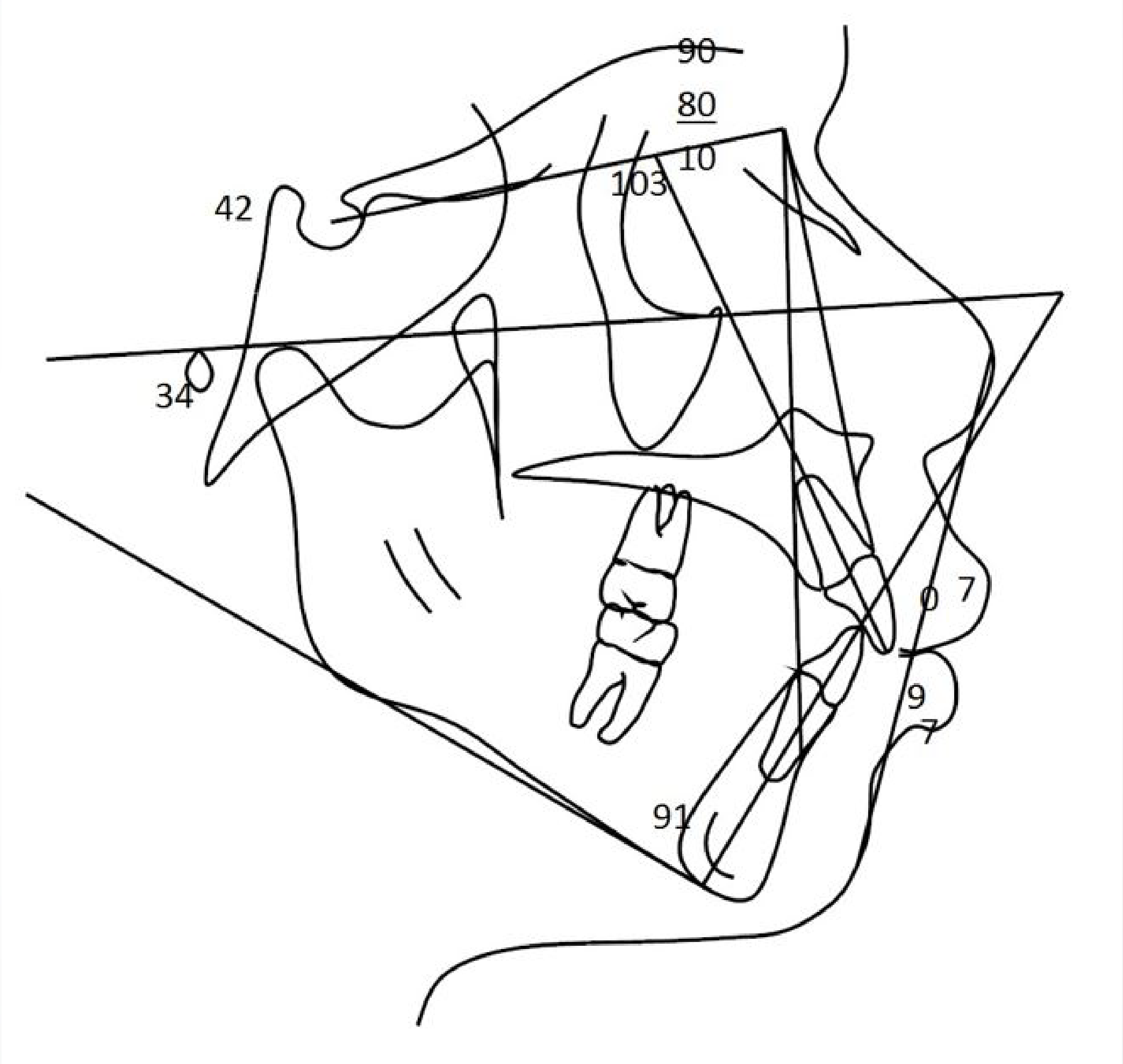
Sample Case #6

Question 2



Sample Case #6

Question 2



Sample Case #6

Question 2

Classification

Domain 1: Data Gathering and Diagnosis

Prompt

Identify the dental findings. Please respond in numbered list format below.

Sample Case #6

Question 2

Fully Proficient Model Response

The examinee's response must include six or more of the following:

1. Class I malocclusion
2. Maxillary crowding
3. Mandibular crowding
4. Blocked out mandibular canines
5. Blocked out maxillary canines
6. Retained primary teeth
7. Deep overbite

Sample Case #6

Question 2

Borderline Proficient Model Response

The examinee's response must include five of the above.

Not Proficient Model Response

The examinee's response includes four or fewer of the above.

Sample Case #6

Question 3

Classification

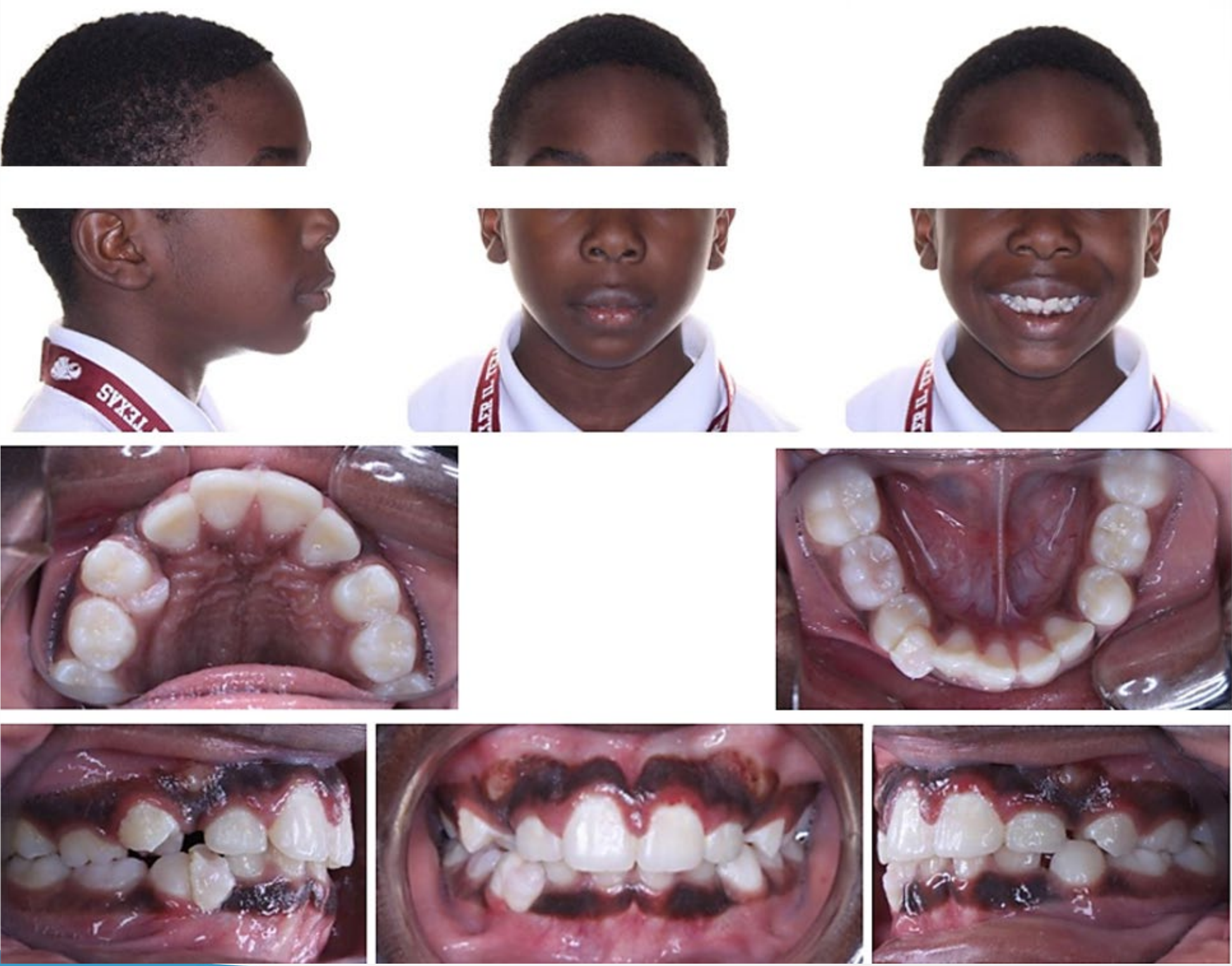
Domain 2: Treatment Objectives and Planning

Prompt

What are the negative consequences of a nonextraction treatment plan? Please respond in numbered list format below.

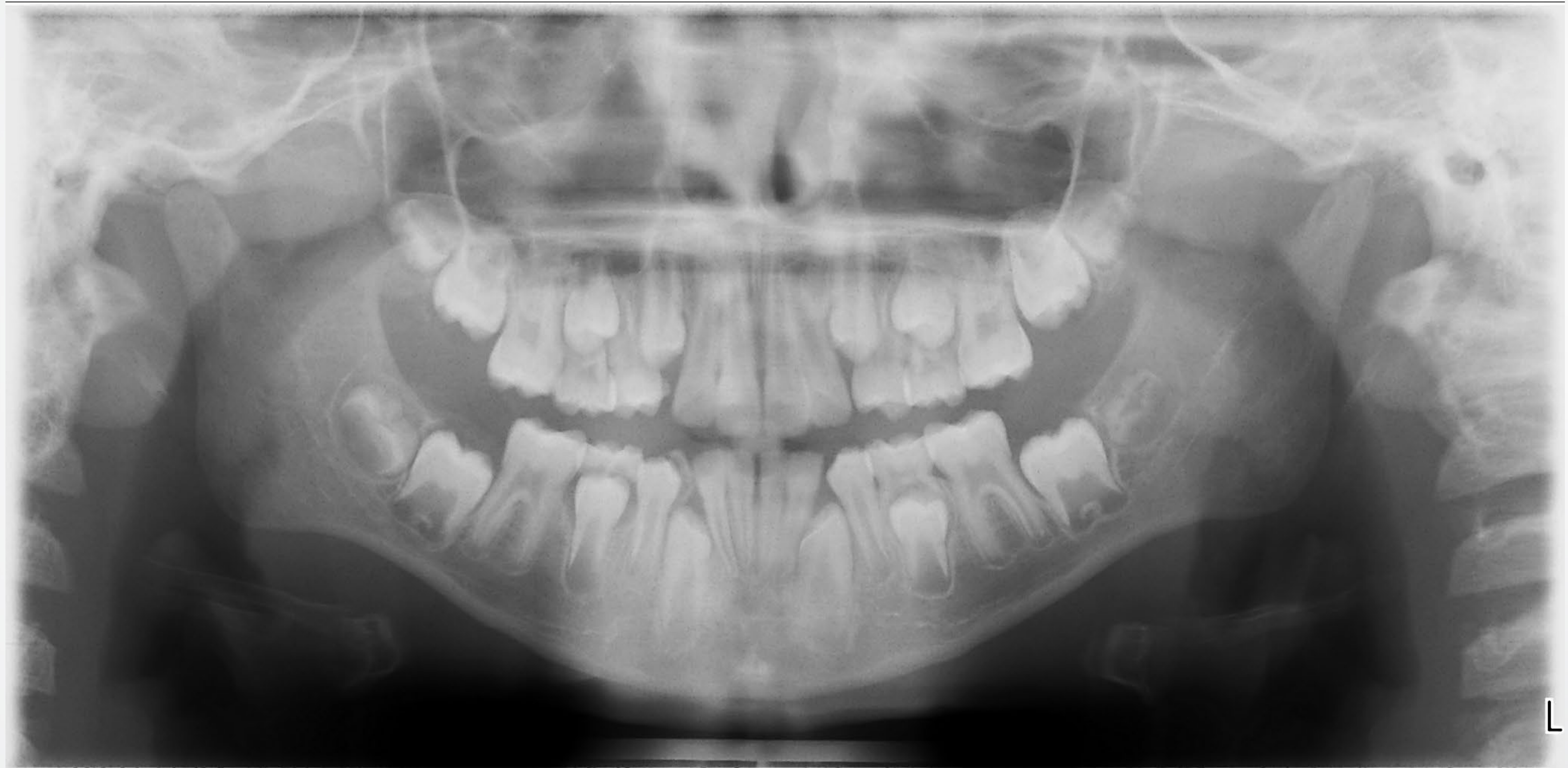Sample Case #6

Question 3



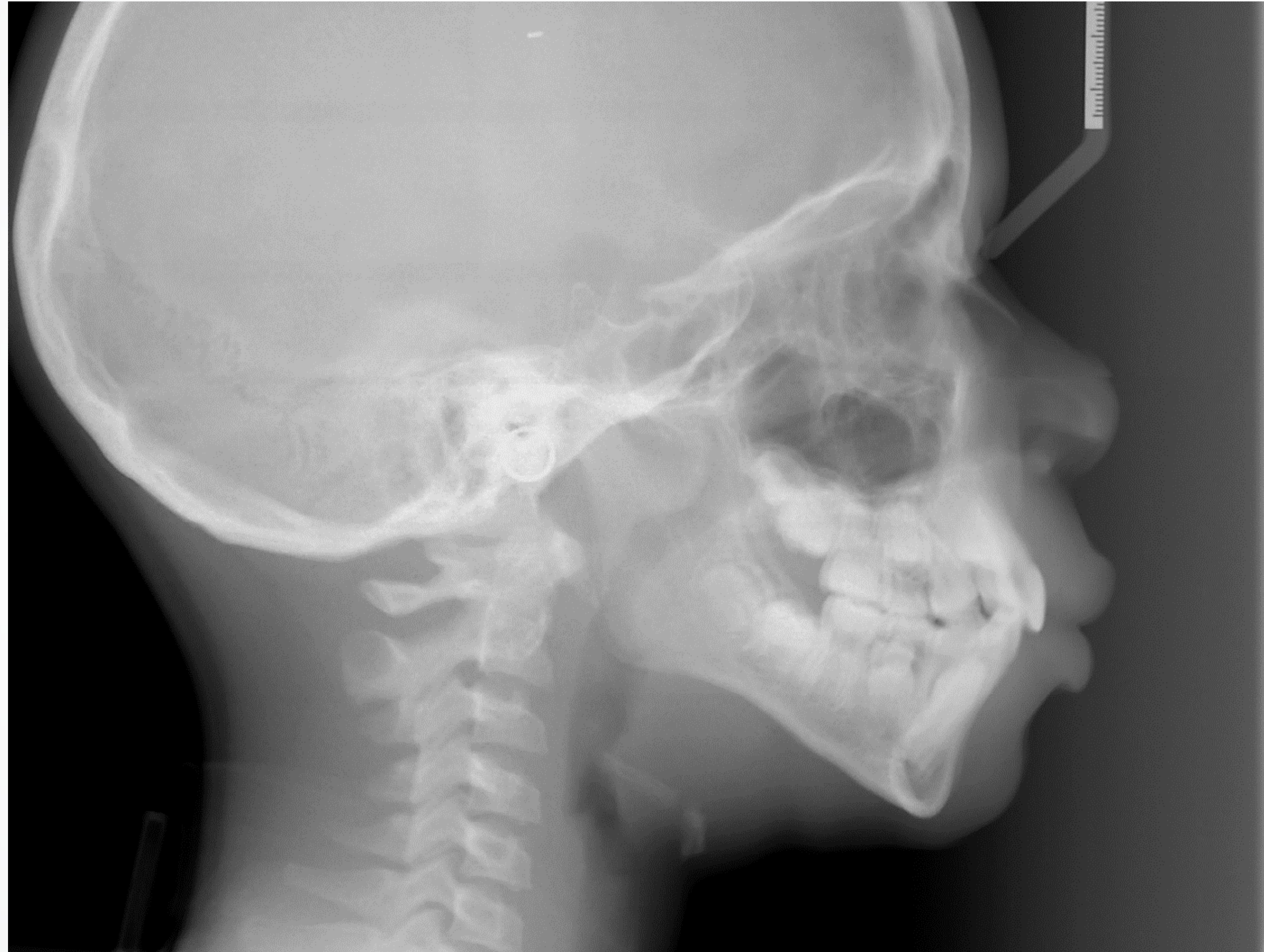Sample Case #6

Question 3



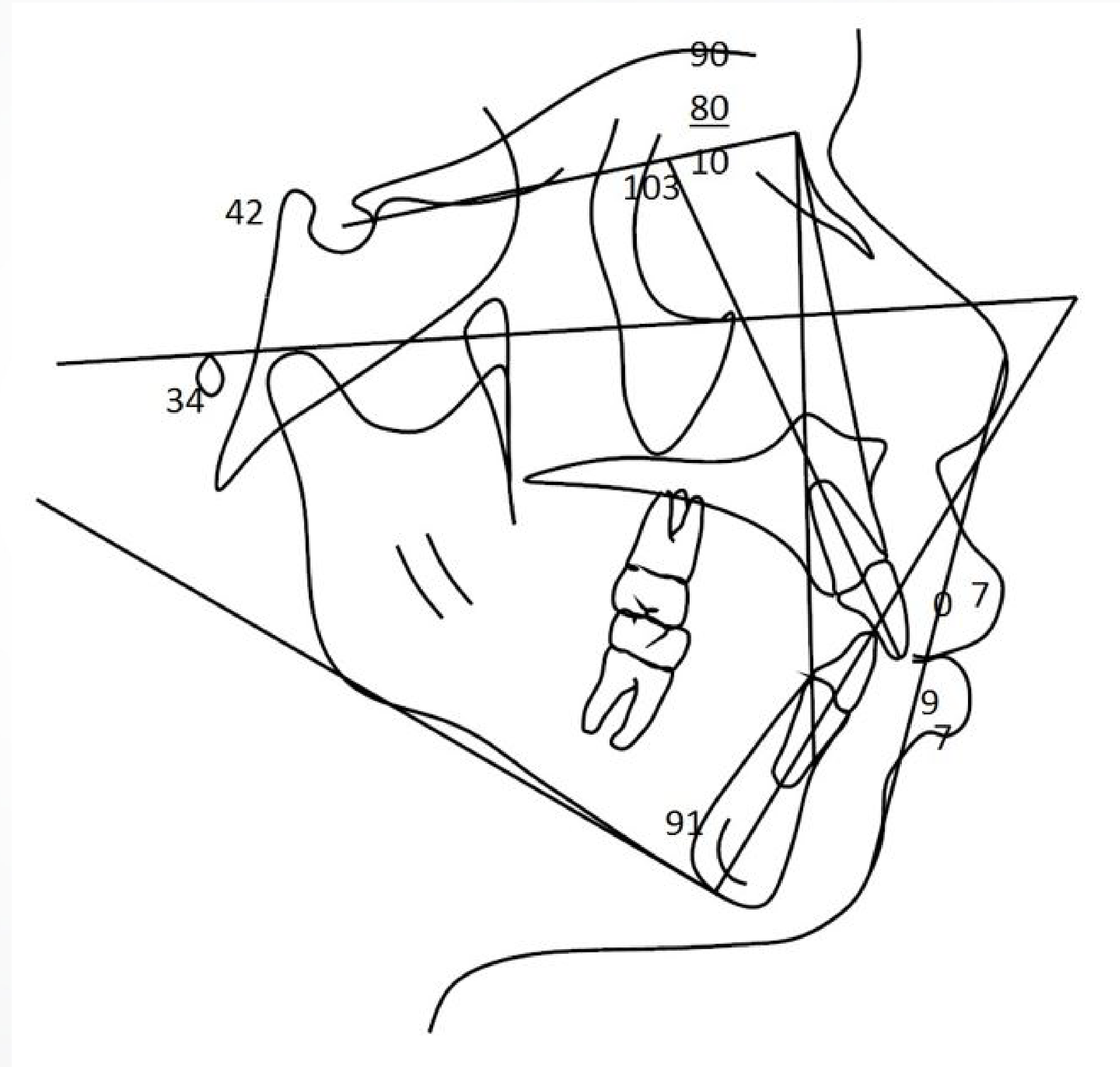
Sample Case #6

Question 3



Sample Case #6

Question 3



Sample Case #6

Question 3

Classification

Domain 2: Treatment Objectives and Planning

Prompt

What are the negative consequences of a nonextraction treatment plan? Please respond in numbered list format below.

Sample Case #6

Question 3

Fully Proficient Model Response

The examinee's response must include five or more of the following:

1. Increased proclination of maxillary incisors (accept increased bimaxillary protrusion)
2. Increased proclination of mandibular incisors (accept increased bimaxillary protrusion)
3. Increased vertical dimension (increased mandibular plane angle)
4. Increased lip incompetence
5. Increased facial convexity
6. Compromised periodontal condition

Sample Case #6

Question 3

Borderline Proficient Model Response

The examinee's response must include four of the above.

Not Proficient Model Response

The examinee's response includes three or fewer of the above.

Sample Case #6

Question 4

Classification

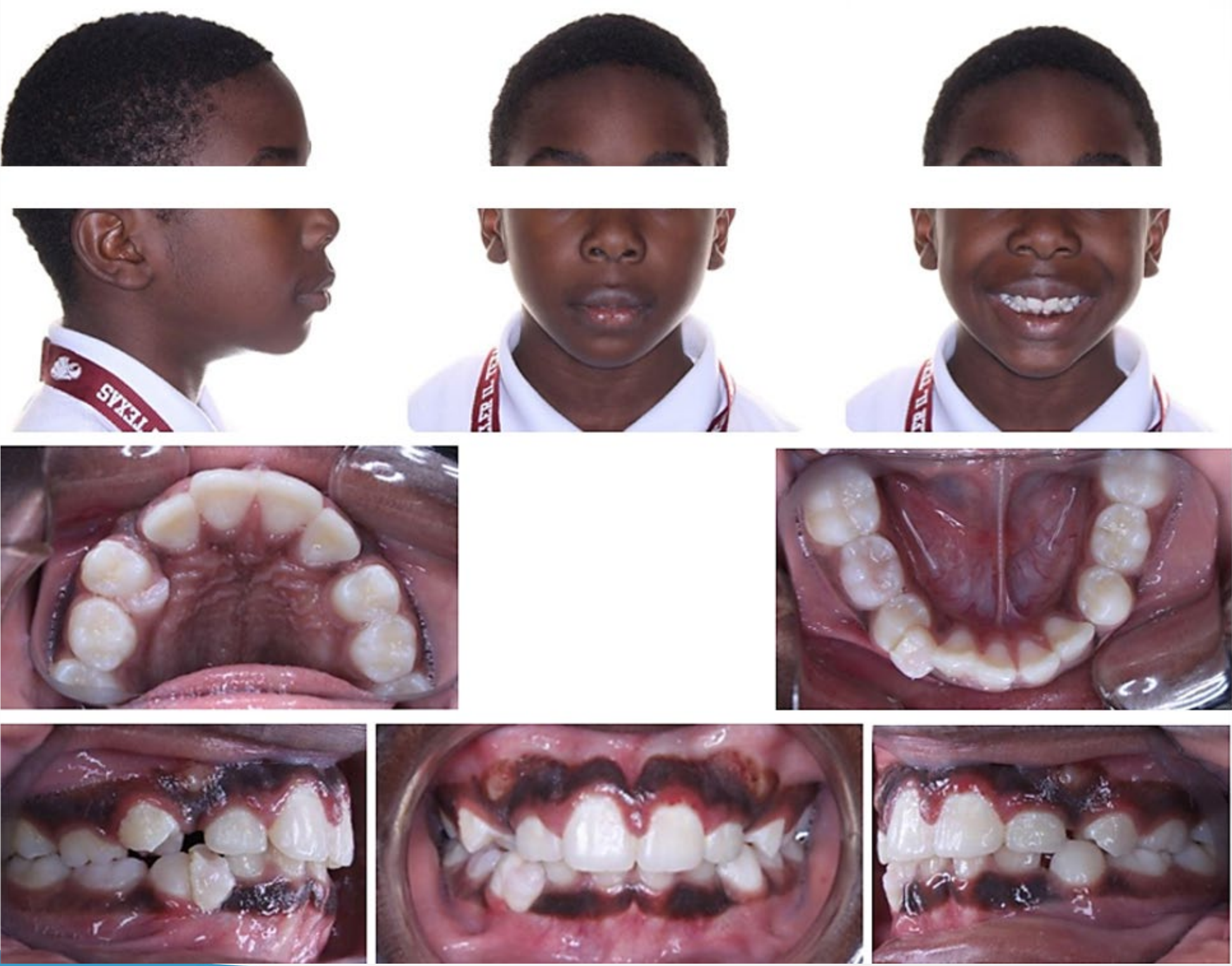
Domain 3: Treatment Implementation and Management

Prompt

List methods to control the vertical dimension if the four first premolars are extracted. Please respond in numbered list format below.

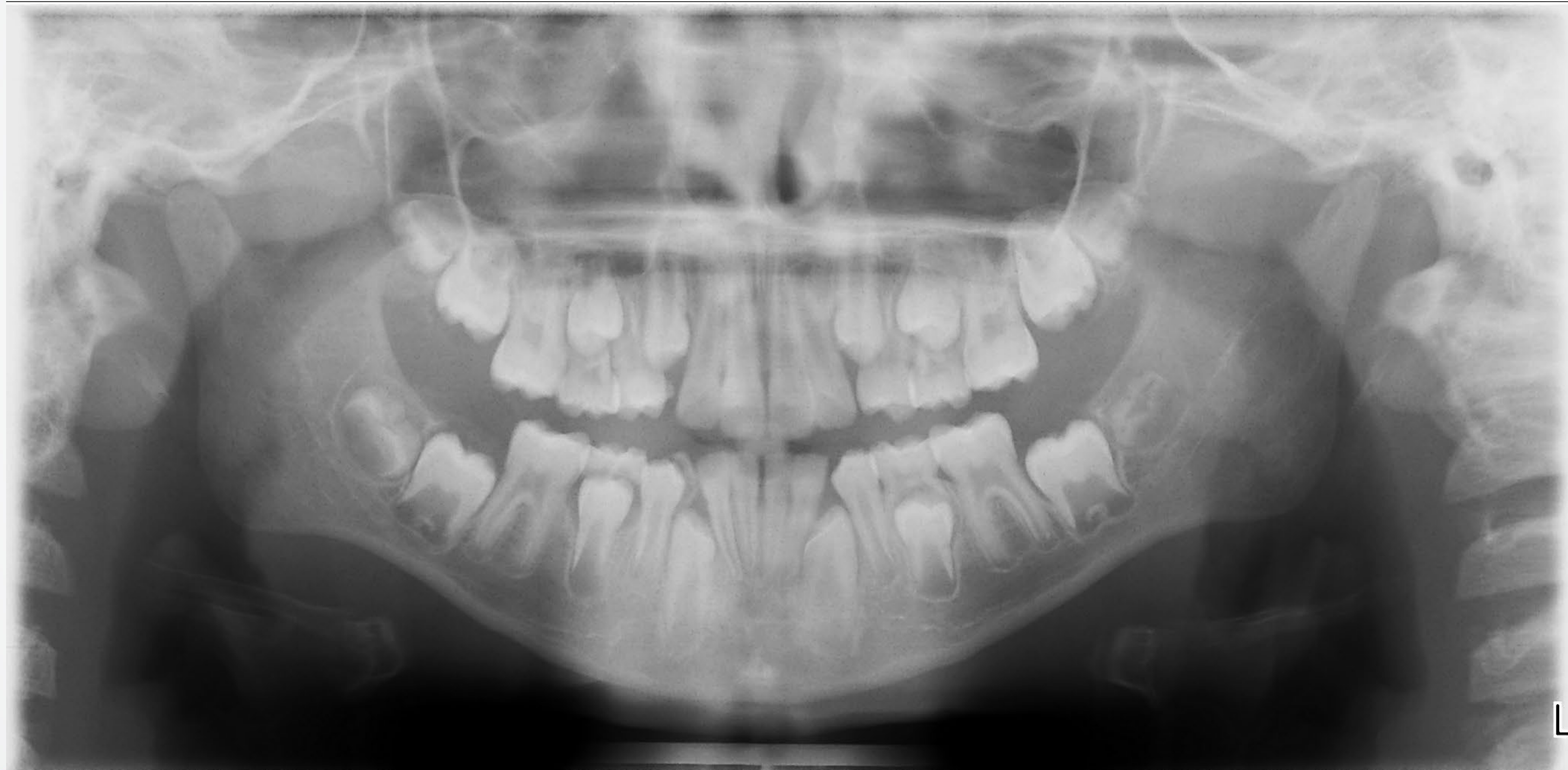Sample Case #6

Question 4



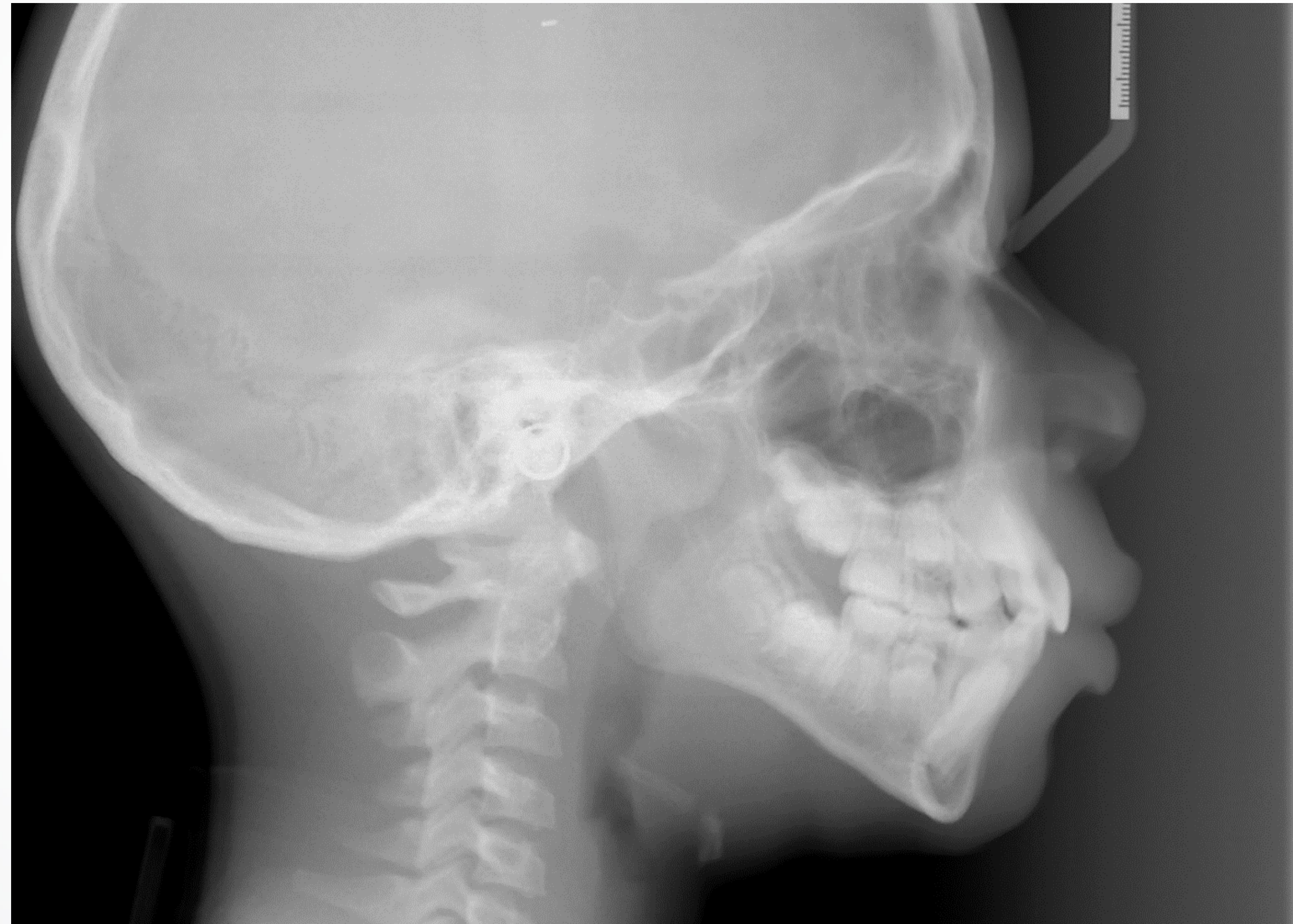Sample Case #6

Question 4



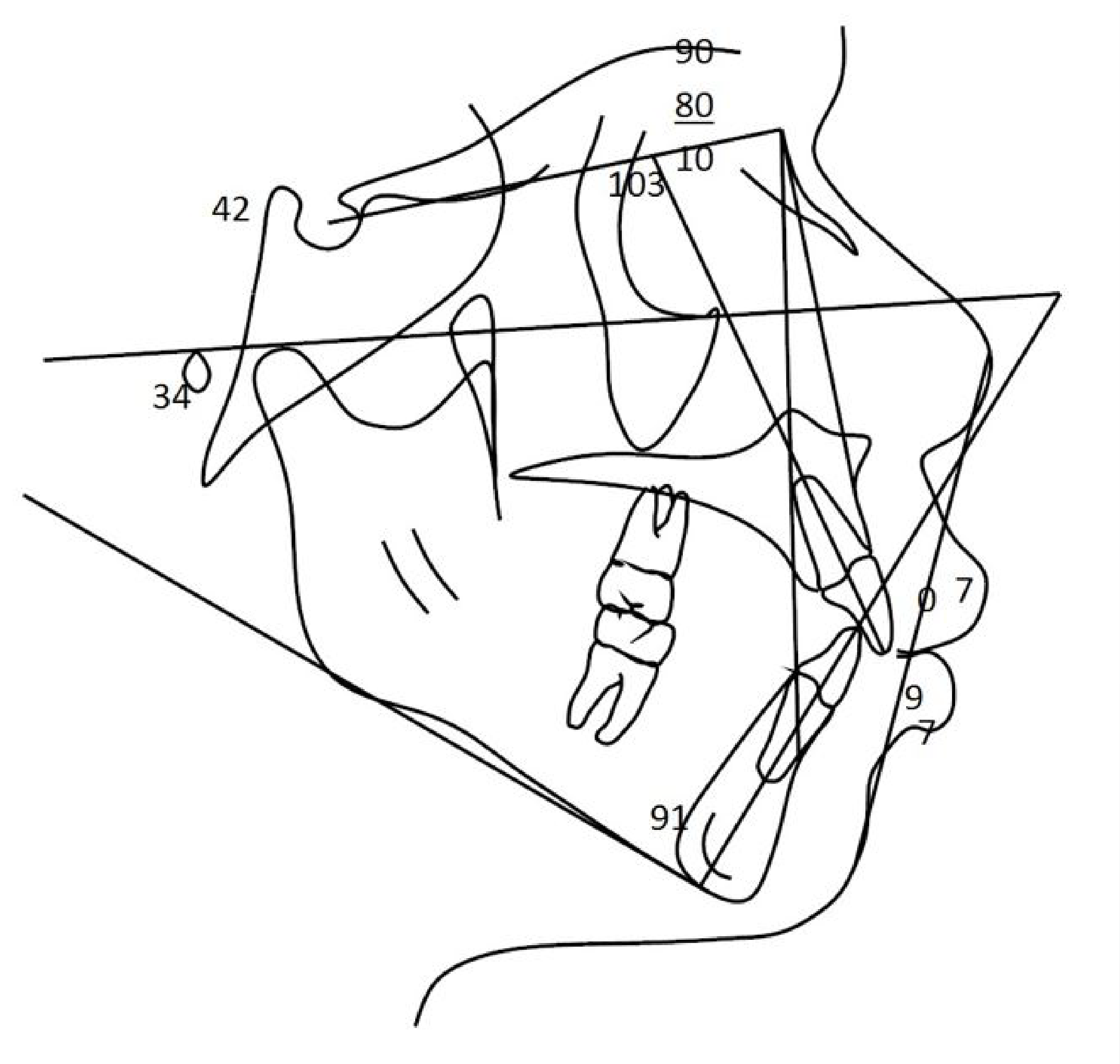
Sample Case #6

Question 4



Sample Case #6

Question 4



Sample Case #6

Question 4

Classification

Domain 3: Treatment Implementation and Management

Prompt

List methods to control the vertical dimension if the four first premolars are extracted. Please respond in numbered list format below.

Sample Case #6

Question 4

Fully Proficient Model Response

The examinee's response must include five or more of the following:

1. High-pull headgear (accept vertical pull chin cup)
2. Maxillary vertical holding appliance (e.g., low-hanging transpalatal arch)
3. Minimize the use of intermaxillary elastics
4. Level the curve of Spee with intrusion arch for mandibular incisors.
5. TADs
6. Posterior bite blocks

Sample Case #6

Question 4

Borderline Proficient Model Response

The examinee's response must include four of the above.

Not Proficient Model Response

The examinee's response includes three or fewer of the above.

Sample Case #7

Sample Case #7

Opening Scenario:

A 12-year, 10-month-old female patient presents for orthodontic treatment with the chief complaint that “I want straight teeth.”

Sample Case #7

Question 1

Classification

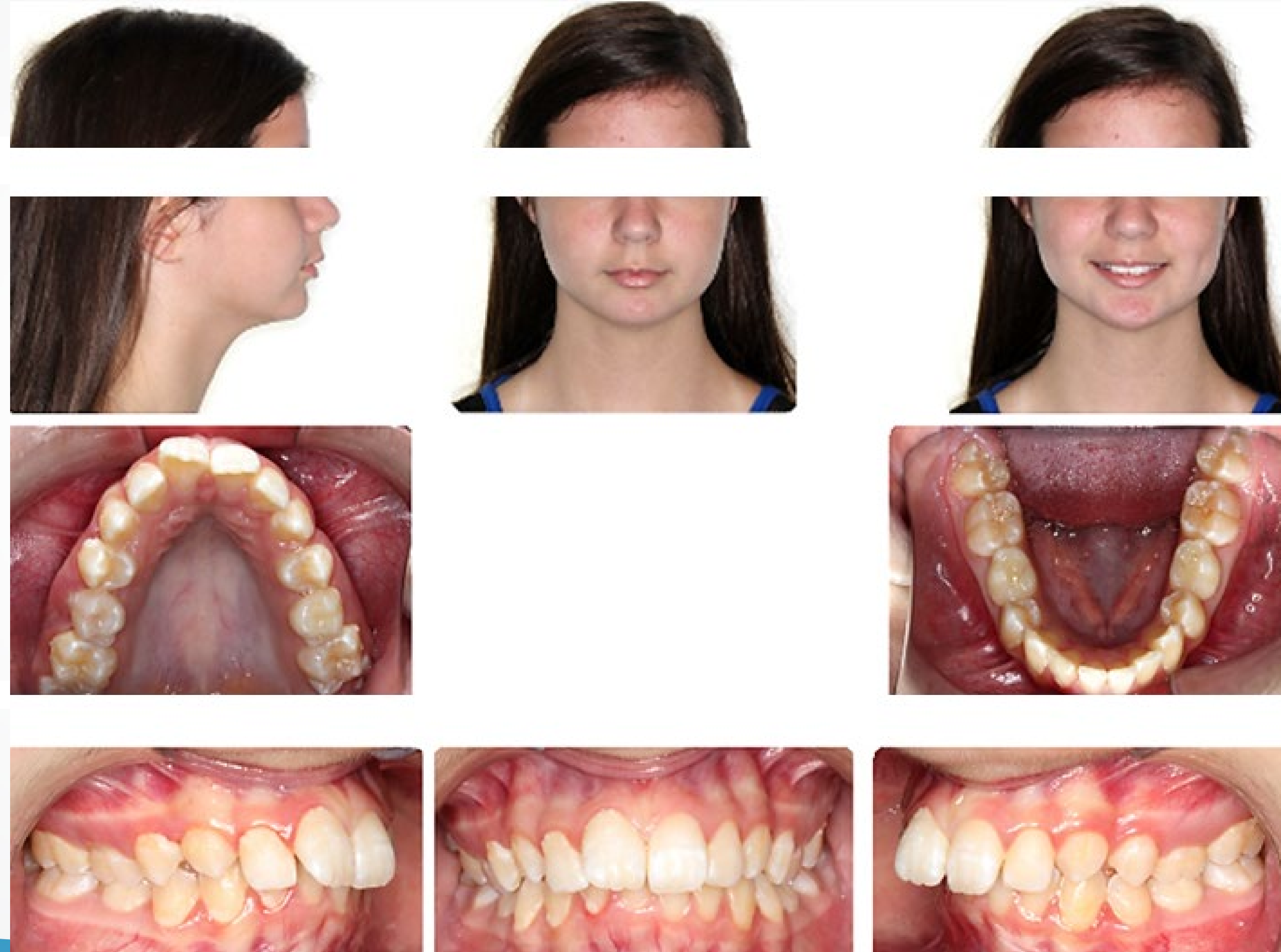
Domain 2: Treatment Objectives and Planning

Prompt

List the maxillary dental objectives of a nonextraction treatment plan. Please respond in numbered list format below.

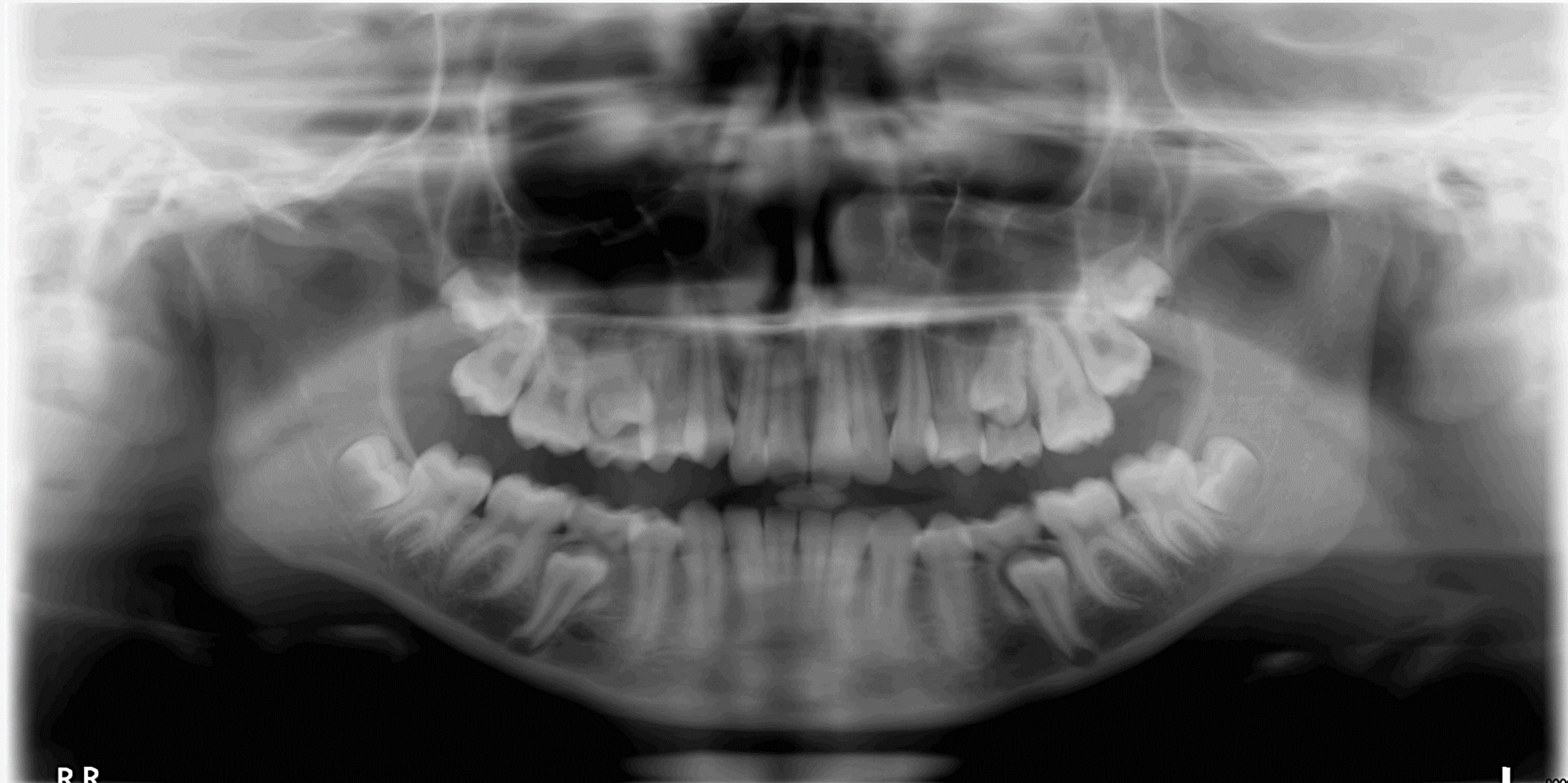Sample Case #7

Question 1



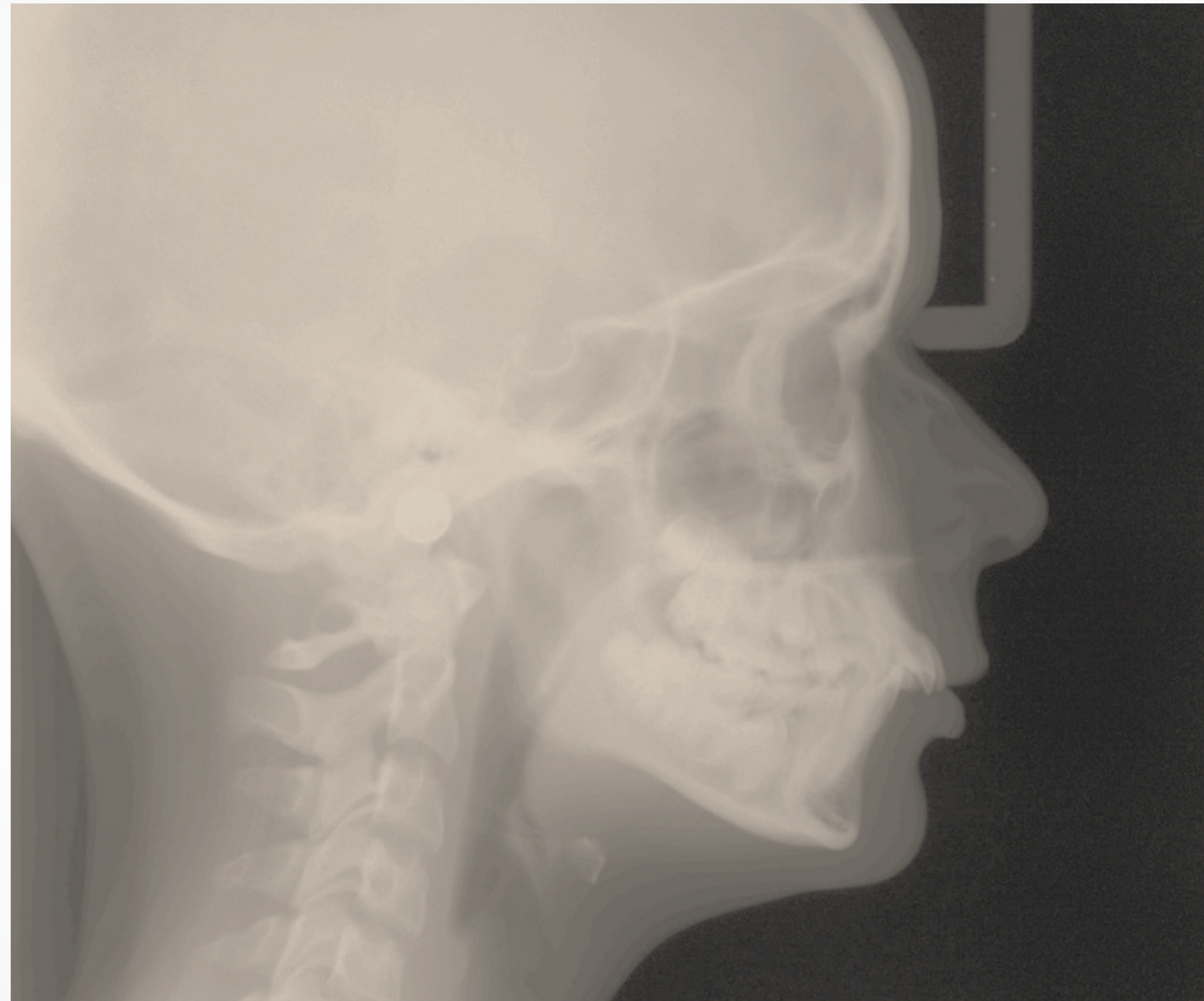Sample Case #7

Question 1



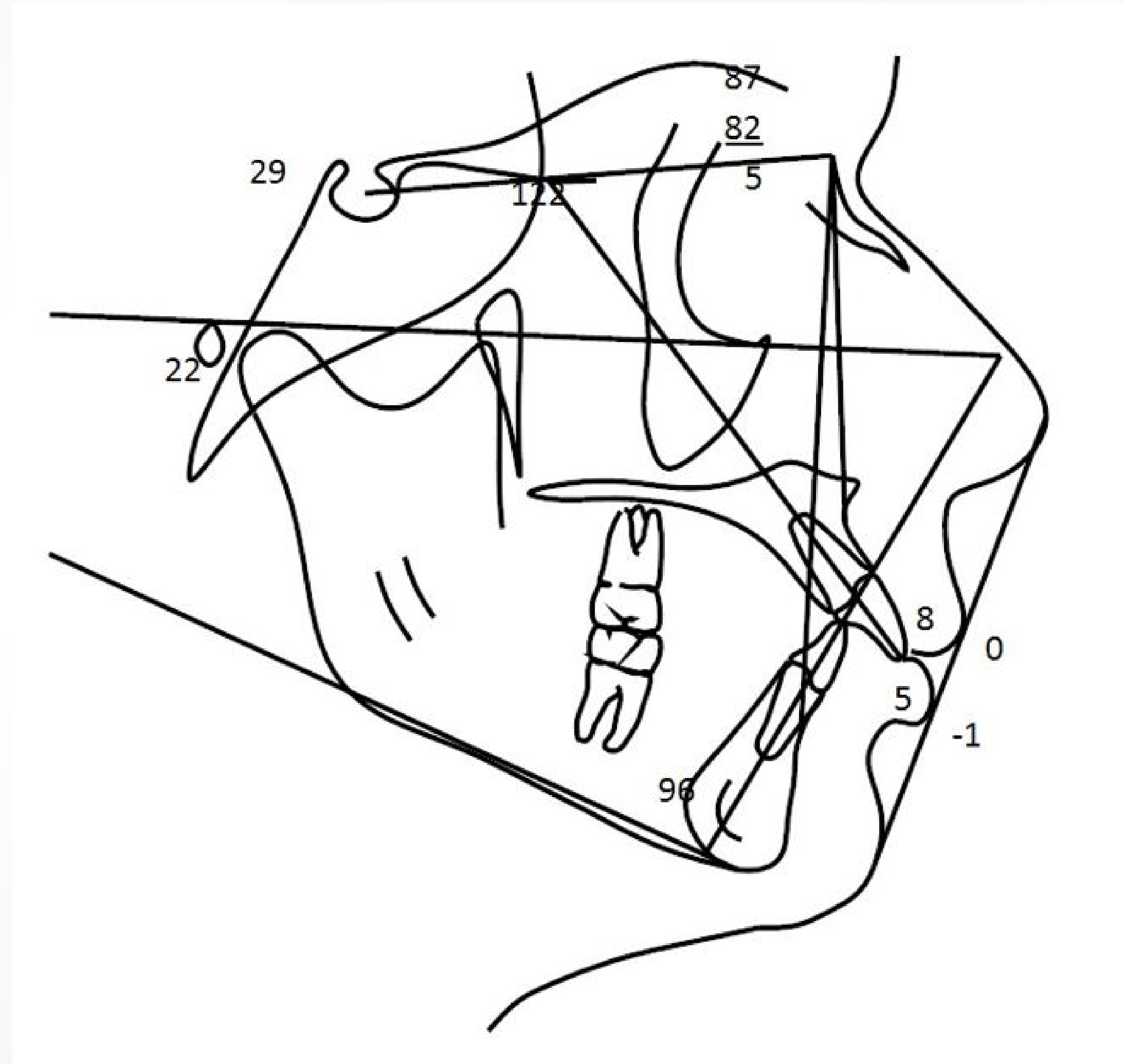
Sample Case #7

Question 1



Sample Case #7

Question 1



Sample Case #7

Question 1

Classification

Domain 2: Treatment Objectives and Planning

Prompt

List the maxillary dental objectives of a nonextraction treatment plan. Please respond in numbered list format below.

Sample Case #7

Question 1

Fully Proficient Model Response

The examinee's response must include five or more of the following:

1. Maintain molar A-P position
2. Maintain molar vertical position
3. Expand posterior teeth
4. Reduce incisor proclination
5. Retract incisors
6. Increase incisal display (accept relative extrusion)

Sample Case #7

Question 1

Borderline Proficient Model Response

The examinee's response must include four of the above.

Not Proficient Model Response

The examinee's response includes three or fewer of the above.

Sample Case #7

Question 2

Classification

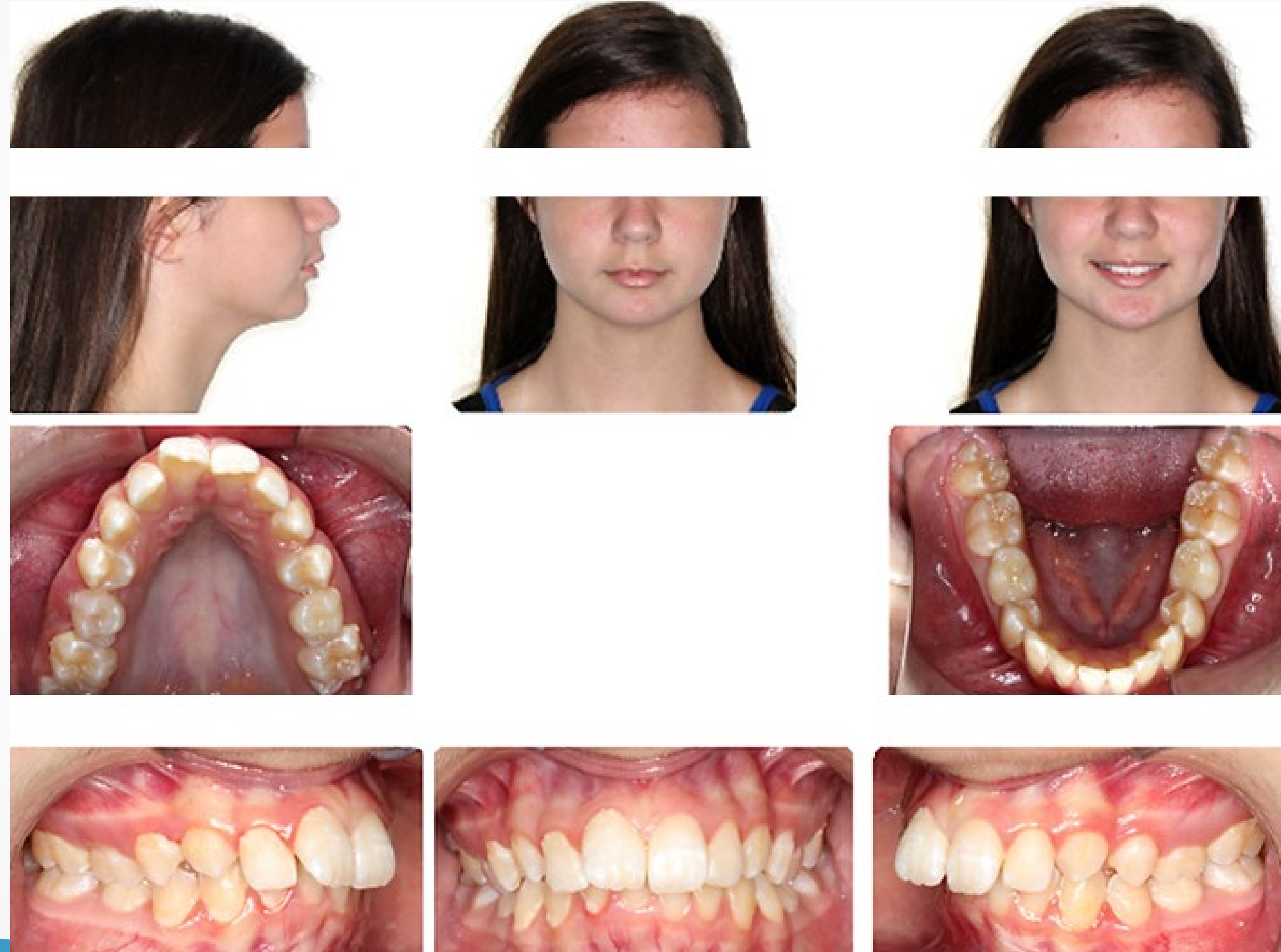
Domain 3: Treatment Implementation and Management

Prompt

What are appropriate methods to level the curve of Spee? Please respond in numbered list format below.

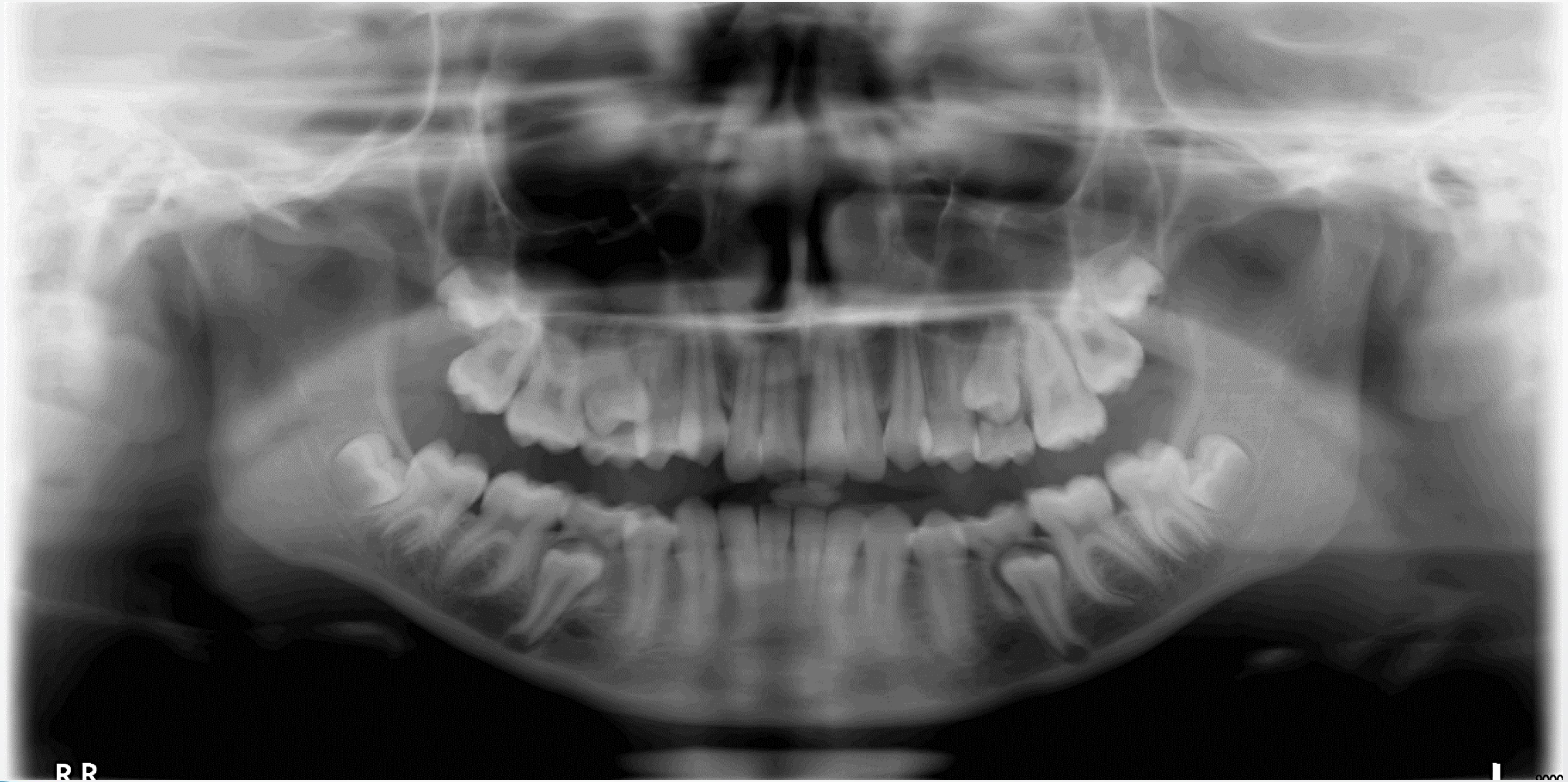Sample Case #7

Question 2



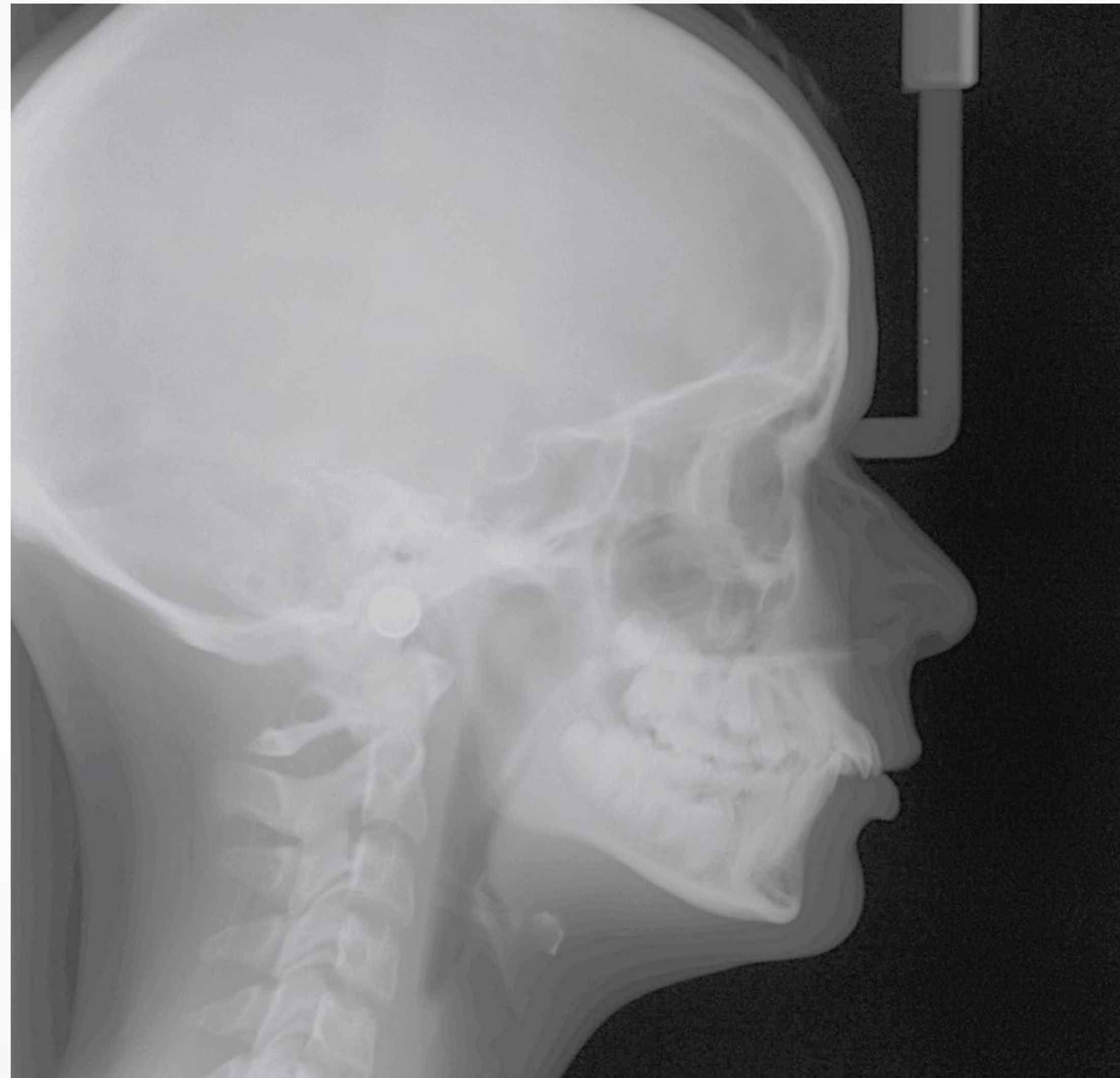Sample Case #7

Question 2



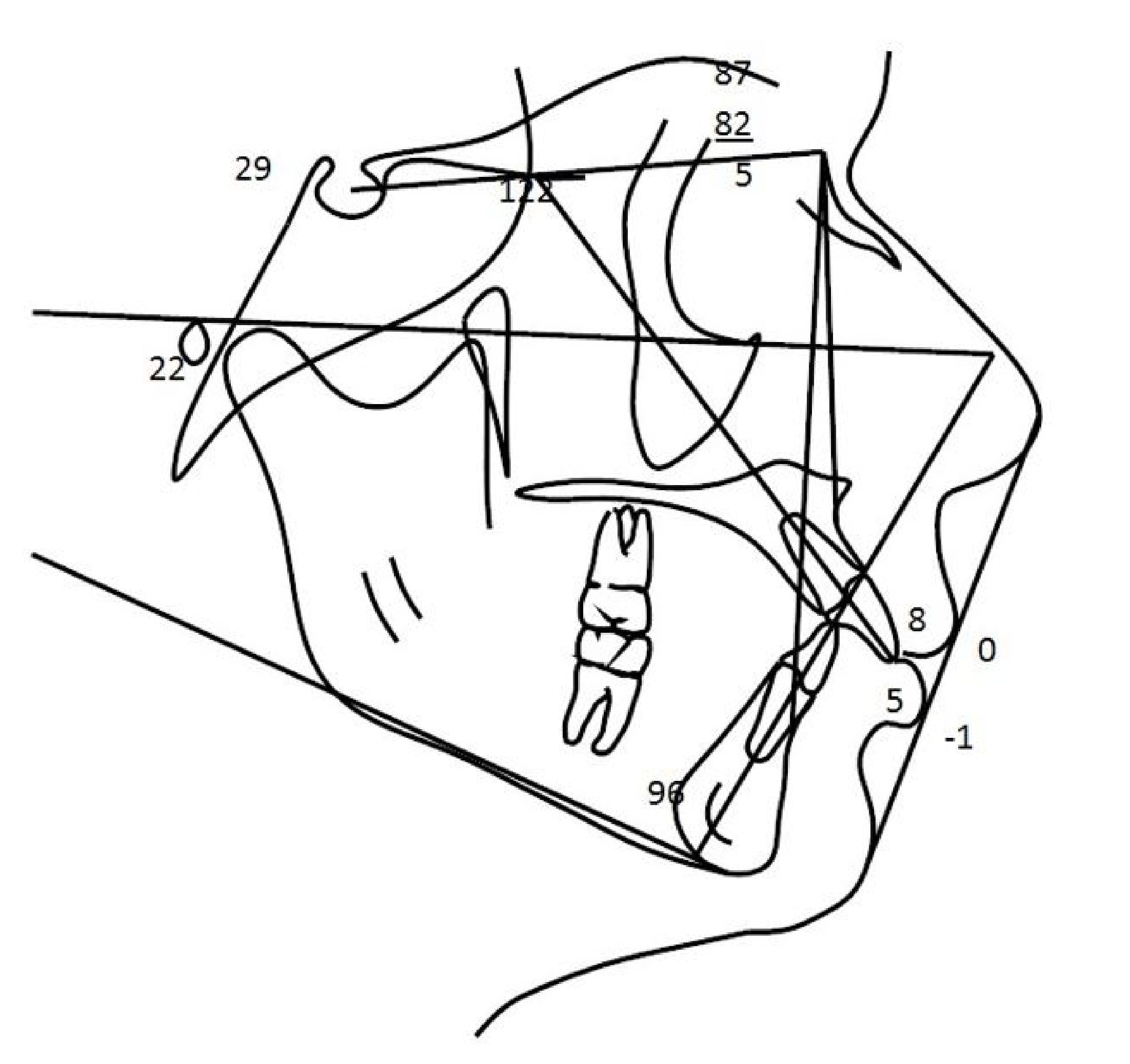
Sample Case #7

Question 2



Sample Case #7

Question 2



Sample Case #7

Question 2

Classification

Domain 3: Treatment Implementation and Management

Prompt

What are appropriate methods to level the curve of Spee? Please respond in numbered list format below.

Sample Case #7

Question 2

Fully Proficient Model Response

The examinee's response must include all of the following:

1. Large dimension rectangular wire with reverse curve of Spee, tied back or cinched back
2. Utility arch to intrude mandibular anterior teeth
3. TADs to aid in the intrusion of the mandibular incisors

Sample Case #7

Question 2

Borderline Proficient Model Response

The examinee's response must include two of the above.

Not Proficient Model Response

The examinee's response includes one or none of the above.

Sample Case #7

Question 3

Classification

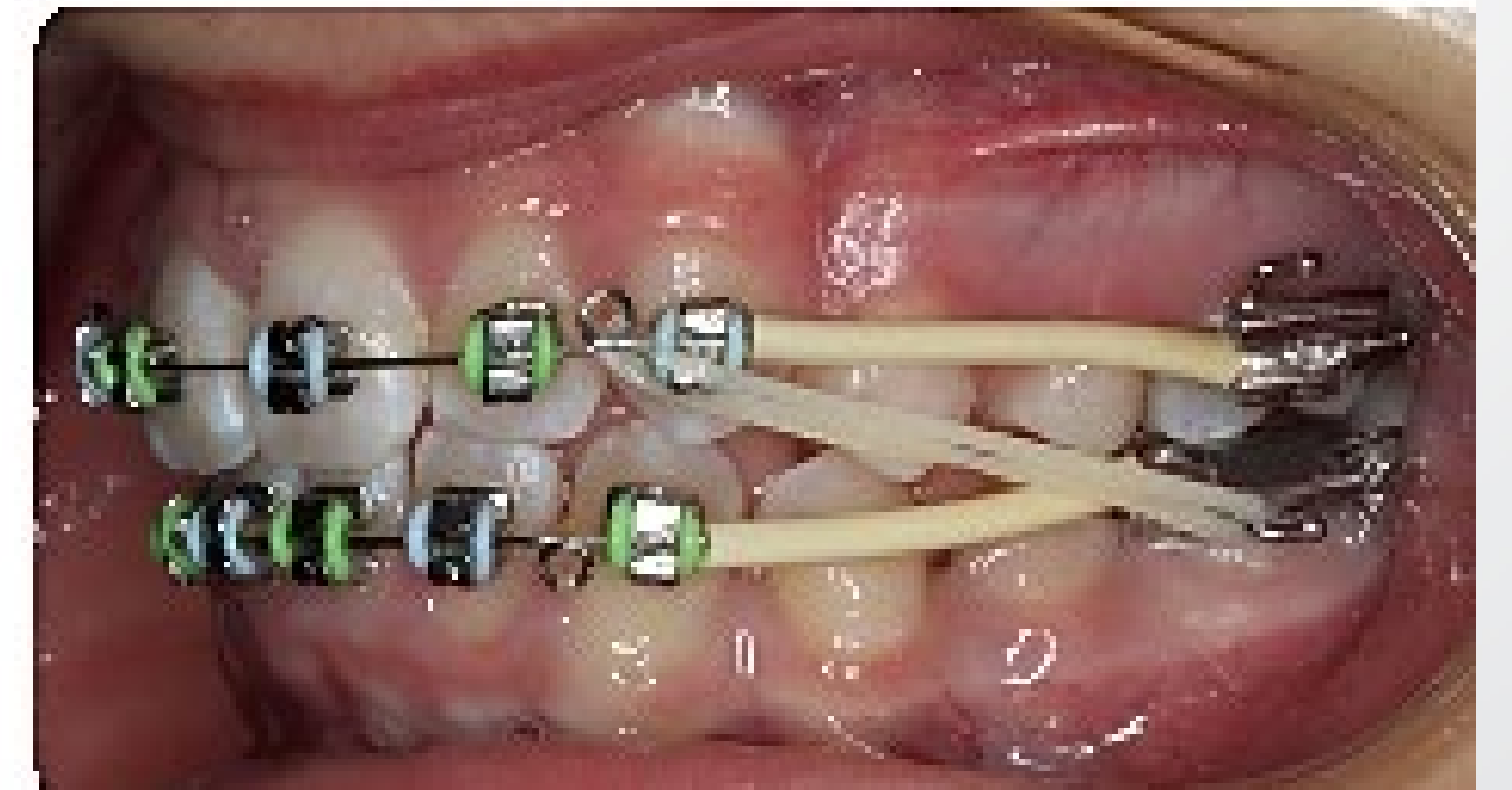
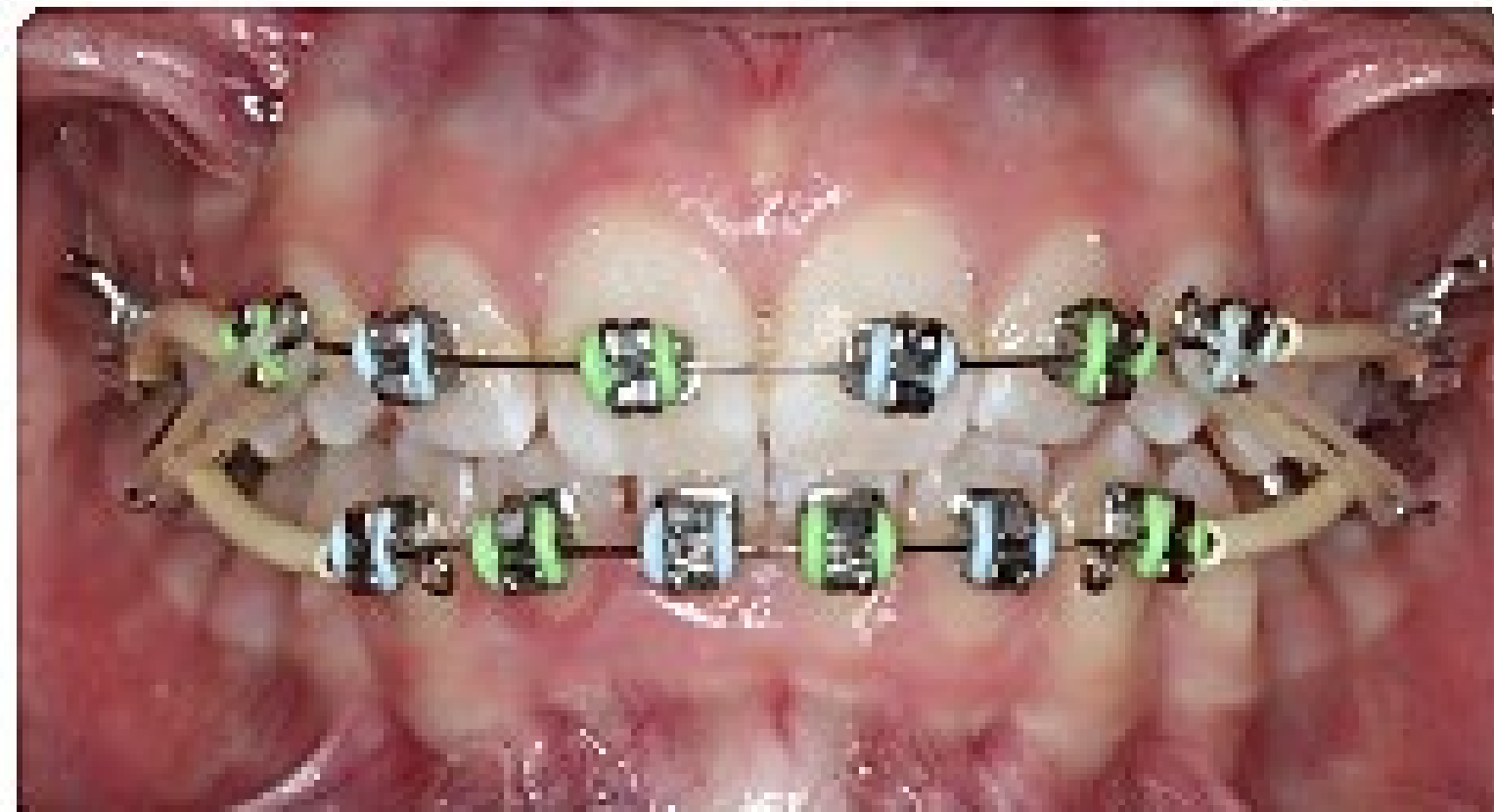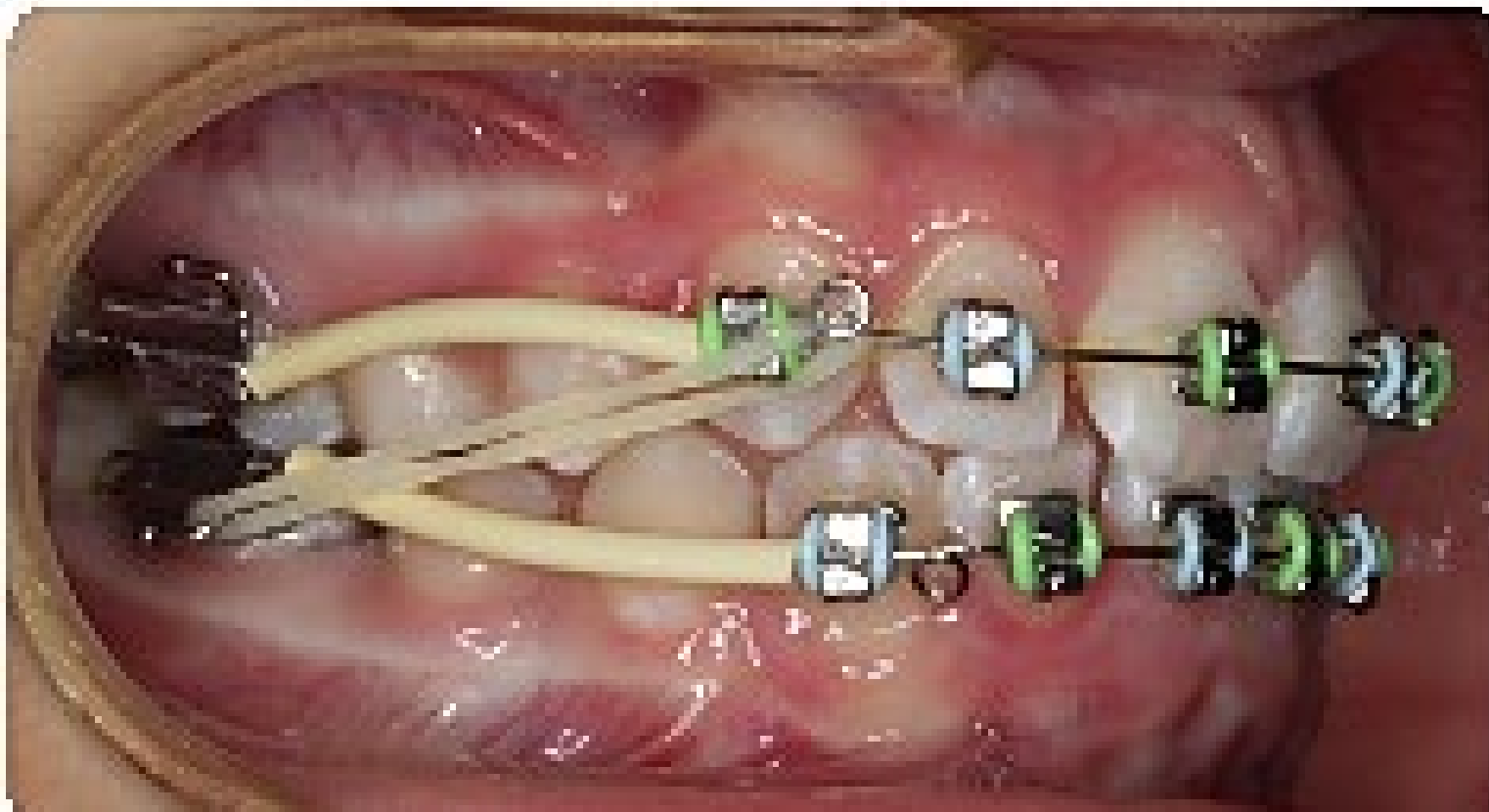
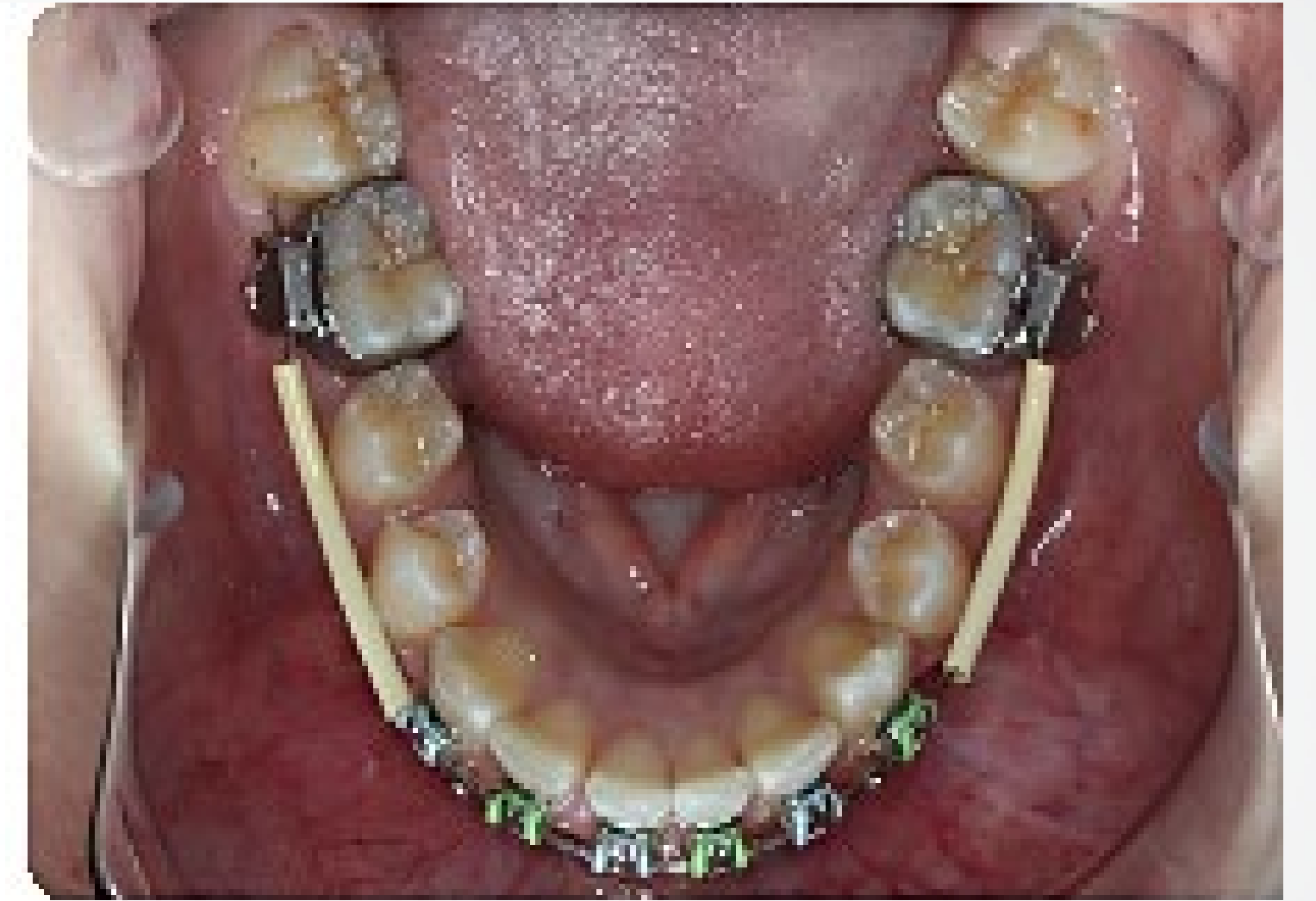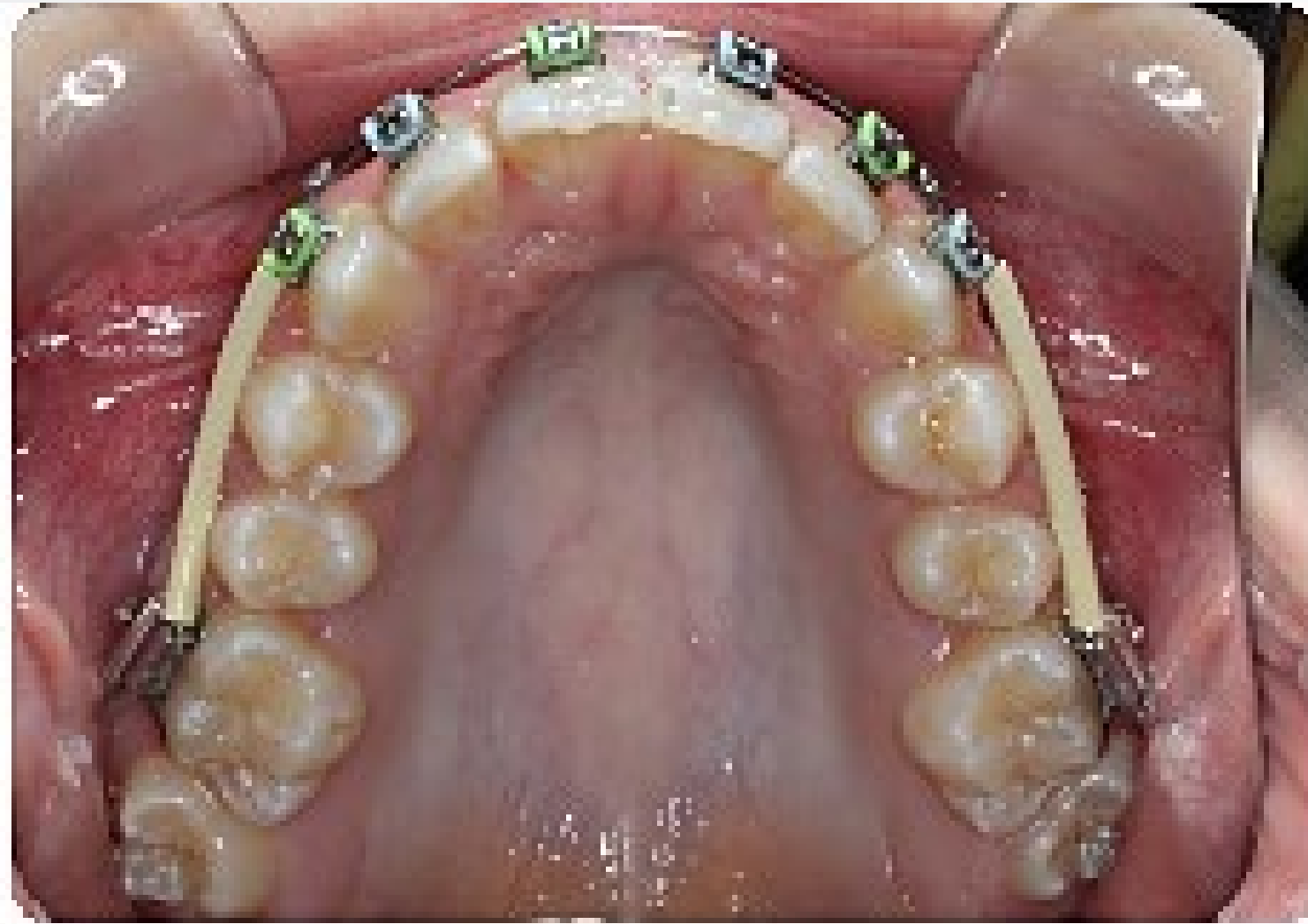Domain 3: Treatment Implementation and Management

Prompt

List the concerns associated with treatment at this point. Please respond in numbered list format below.

Sample Case #7

Question 3



Sample Case #7

Question 3

Classification

Domain 3: Treatment Implementation and Management

Prompt

List the concerns associated with treatment at this point. Please respond in numbered list format below.

Sample Case #7

Question 3

Fully Proficient Model Response

The examinee's response must include five or more of the following:

1. Rotations of the maxillary molars
2. Rotations of the mandibular molars
3. Proclination of the mandibular incisors
4. Lingual inclination of the mandibular first molars
5. Class II elastics on a round wire.
6. All teeth not bonded

Sample Case #7

Question 3

Borderline Proficient Model Response

The examinee's response must include four of the above.

Not Proficient Model Response

The examinee's response includes three or fewer of the above.

Sample Case #7

Question 4

Classification

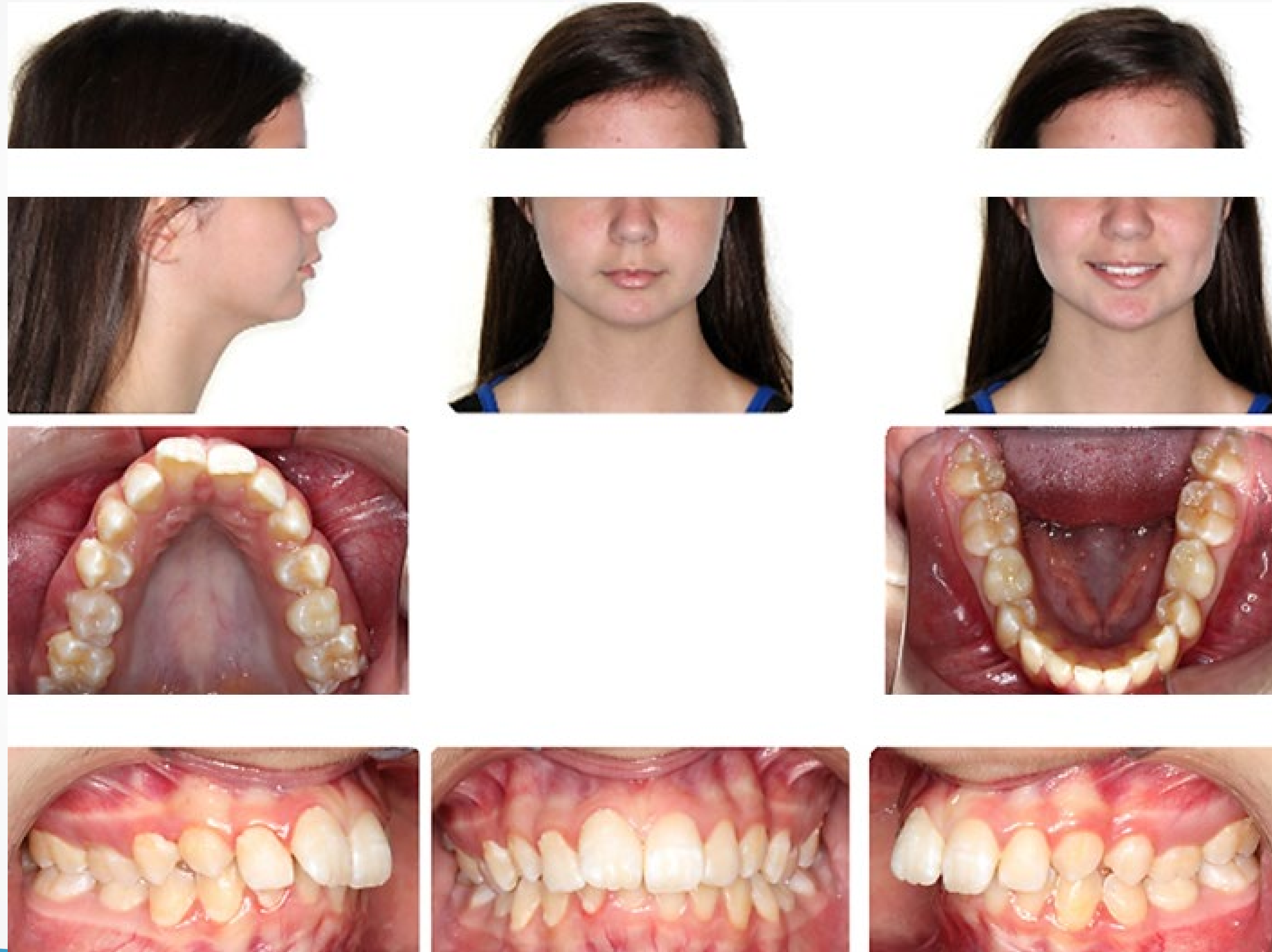
Domain 4: Critical Analysis and Outcomes Assessment

Prompt

Describe the future concerns for the dentition and supporting periodontium. Please respond in numbered list format below.

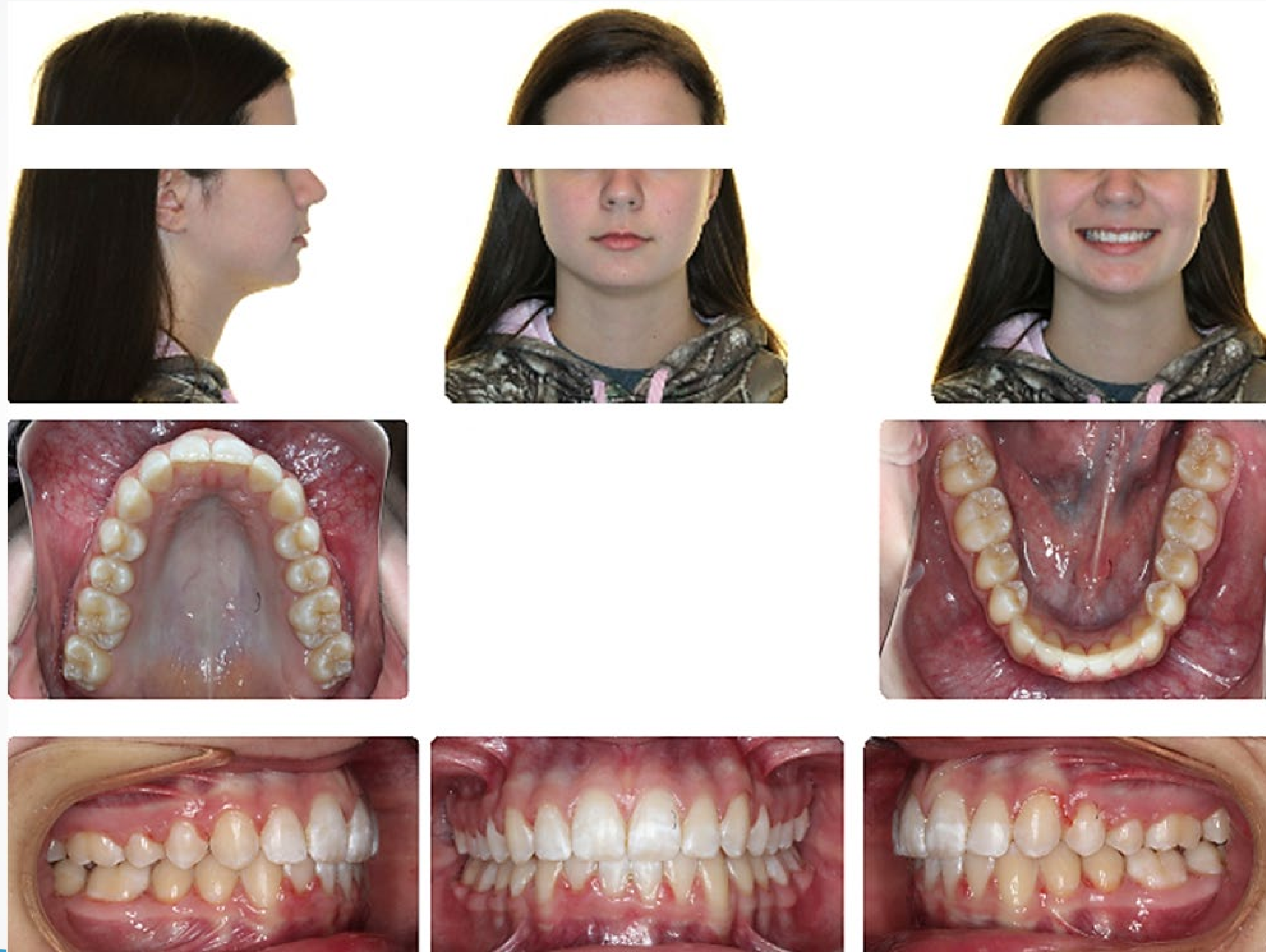
Sample Case #7

Question 4



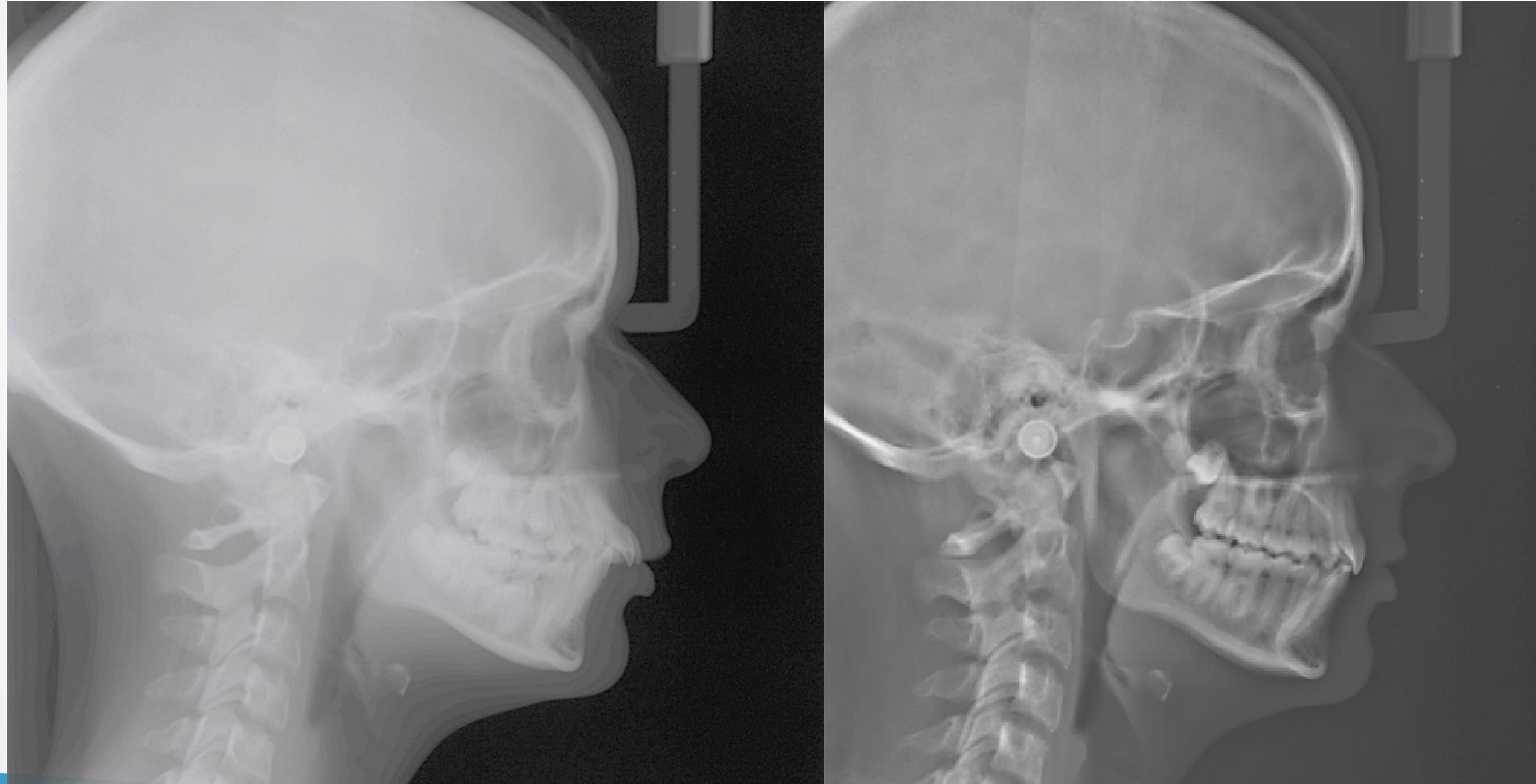
Sample Case #7

Question 4



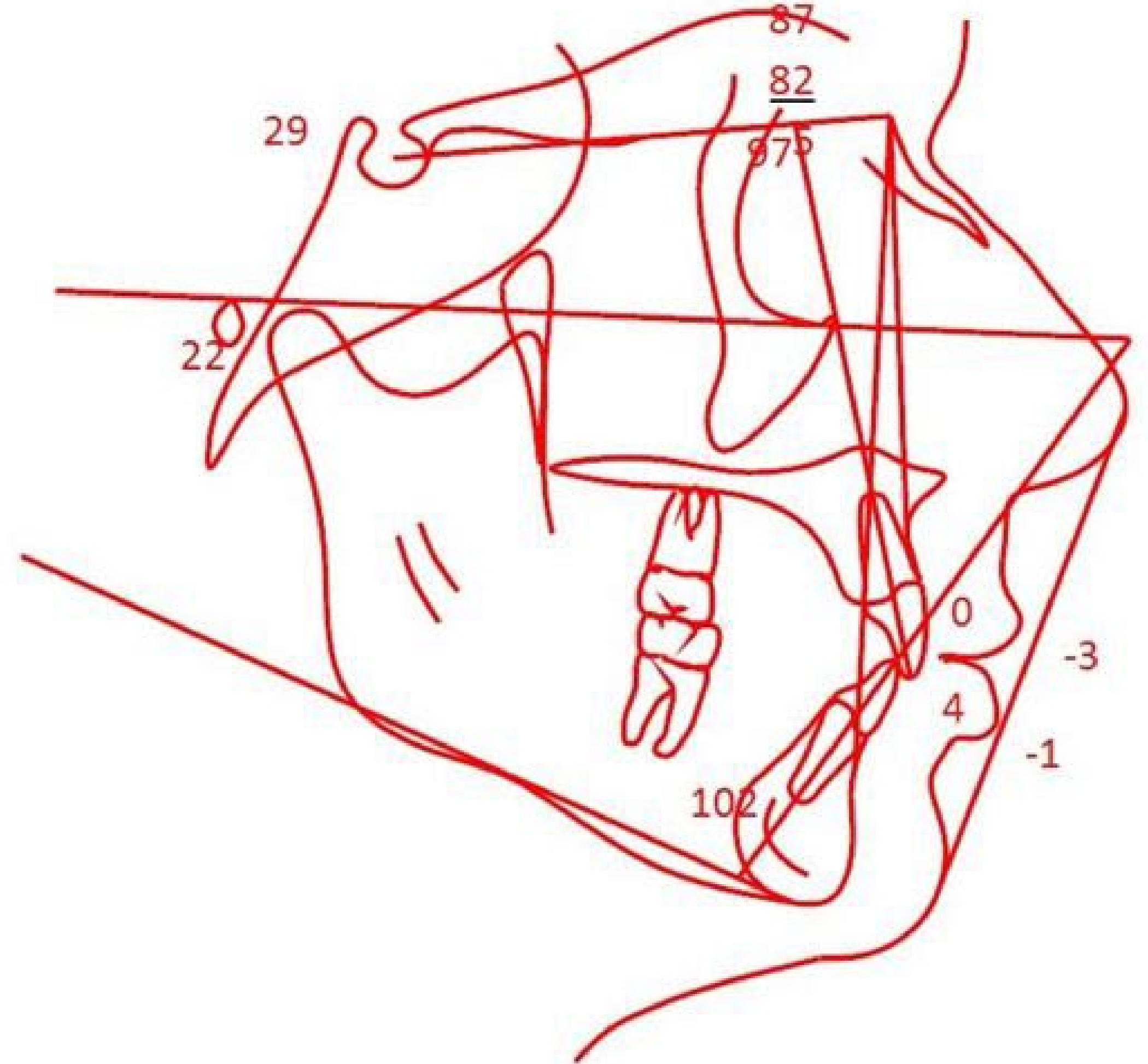
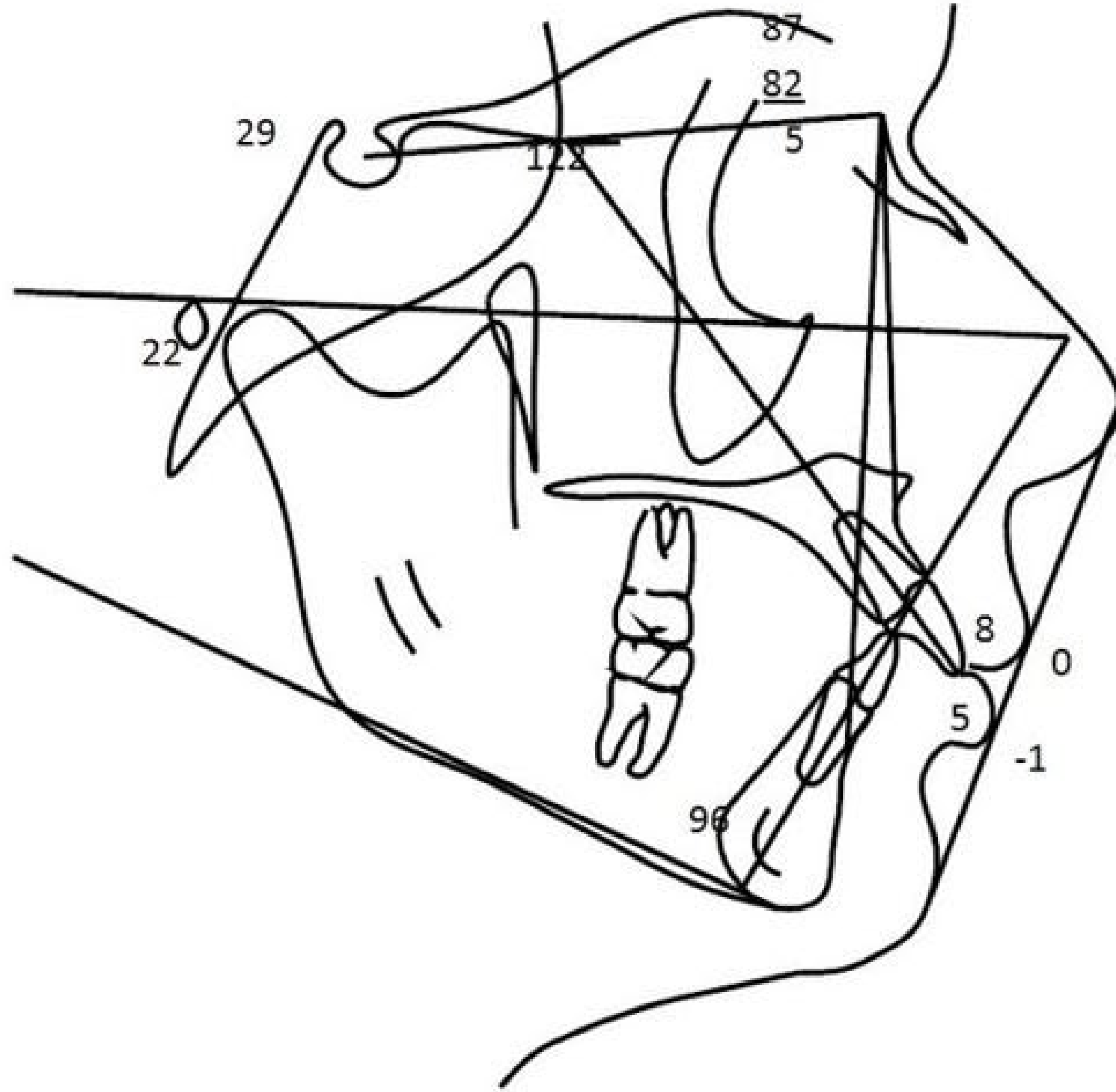
Sample Case #7

Question 4



Sample Case #7

Question 4



Sample Case #7

Question 4

Classification

Domain 4: Critical Analysis and Outcomes Assessment

Prompt

Describe the future concerns for the dentition and supporting periodontium. Please respond in numbered list format below.

Sample Case #7

Question 4

Fully Proficient Model Response

The examinee's response must include all of the following:

1. Gingival recession
2. Periodontal bone loss
3. Mandibular anterior crowding (relapse)
4. Stability of Class II correction

Sample Case #7

Question 4

Borderline Proficient Model Response

The examinee's response must include three of the above.

Not Proficient Model Response

The examinee's response includes two or fewer of the above.

Sample Case #8

Sample Case #8

Question 1

Classification

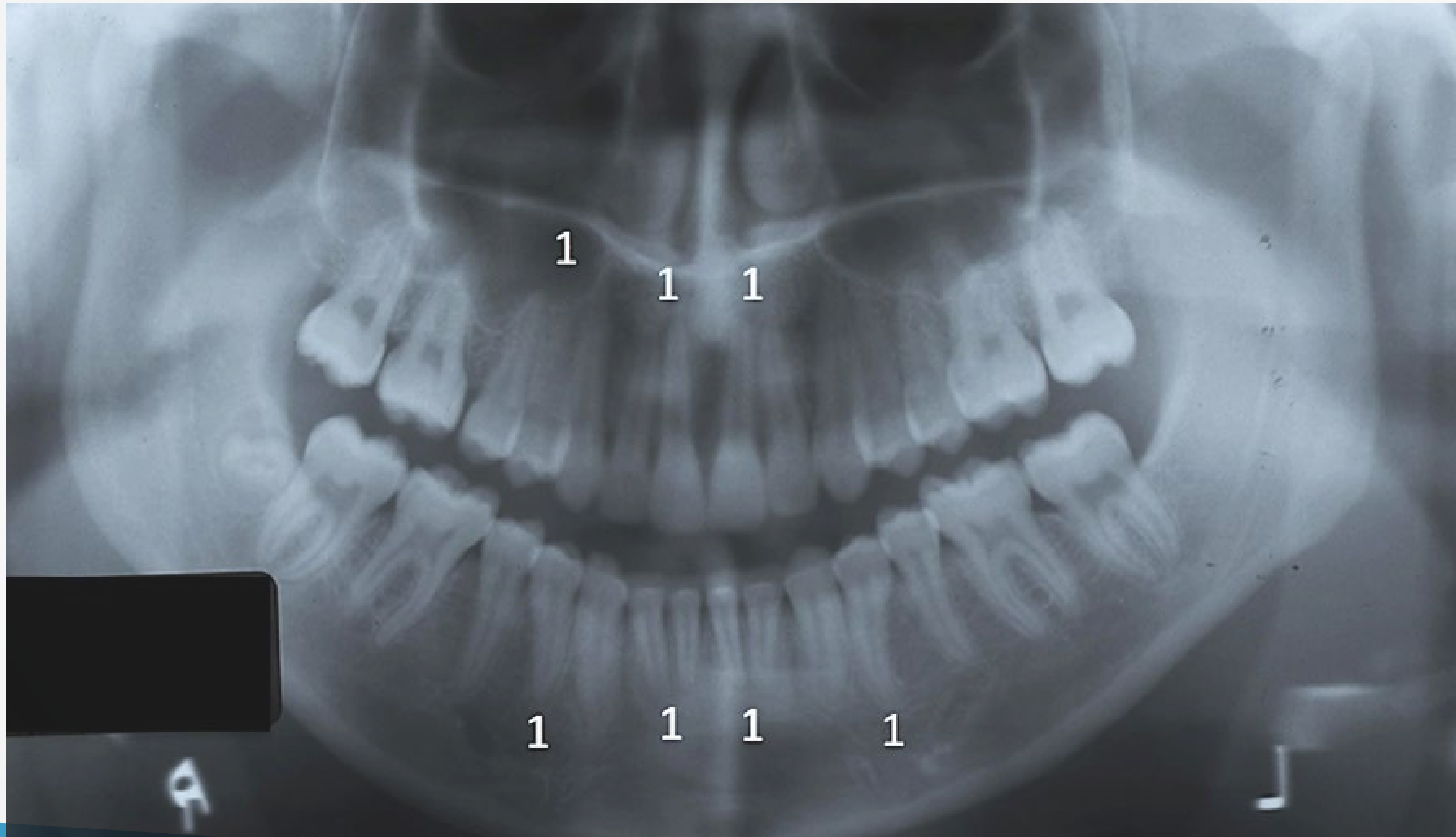
Domain 4: Critical Analysis and Outcomes Assessment

Prompt

What is the CR-Eval score for root angulation?

Sample Case #8

Question 1



Sample Case #8

Question 1

Classification

Domain 4: Critical Analysis and Outcomes Assessment

Prompt

What is the CR-Eval score for root angulation?

Sample Case #8

Question 1

The CR-Eval score for Root Angulation is 7.

Sample Case #9

Sample Case #9

Question 1

Opening Scenario:

A 22-year-old male patient presents with the chief complaint that “two of my front teeth are crooked and stick into my lip.”

Sample Case #9

Question 1

Classification

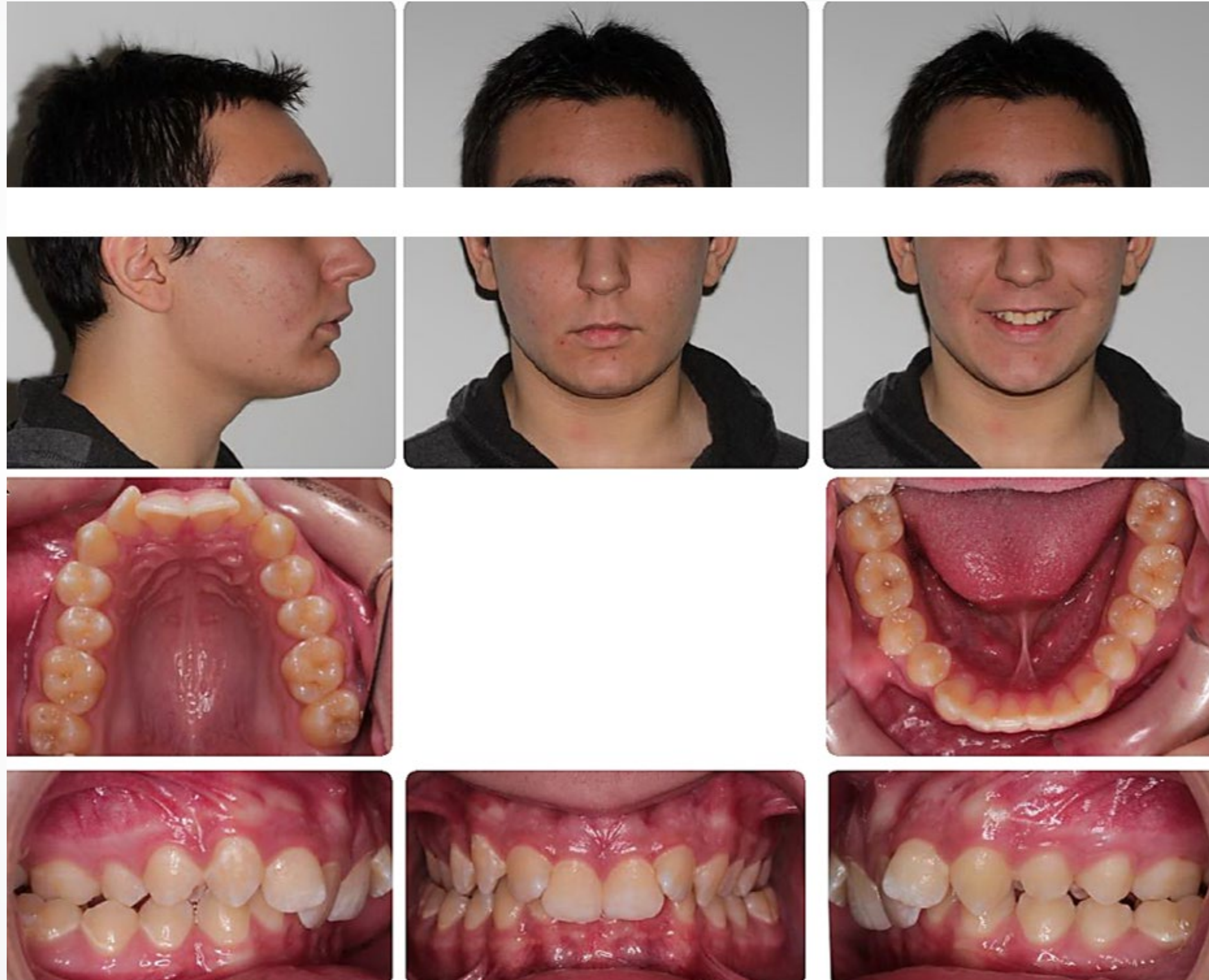Domain 1: Data Gathering and Diagnosis

Prompt

Provide a facial diagnosis for this patient. Please respond in numbered list format below.

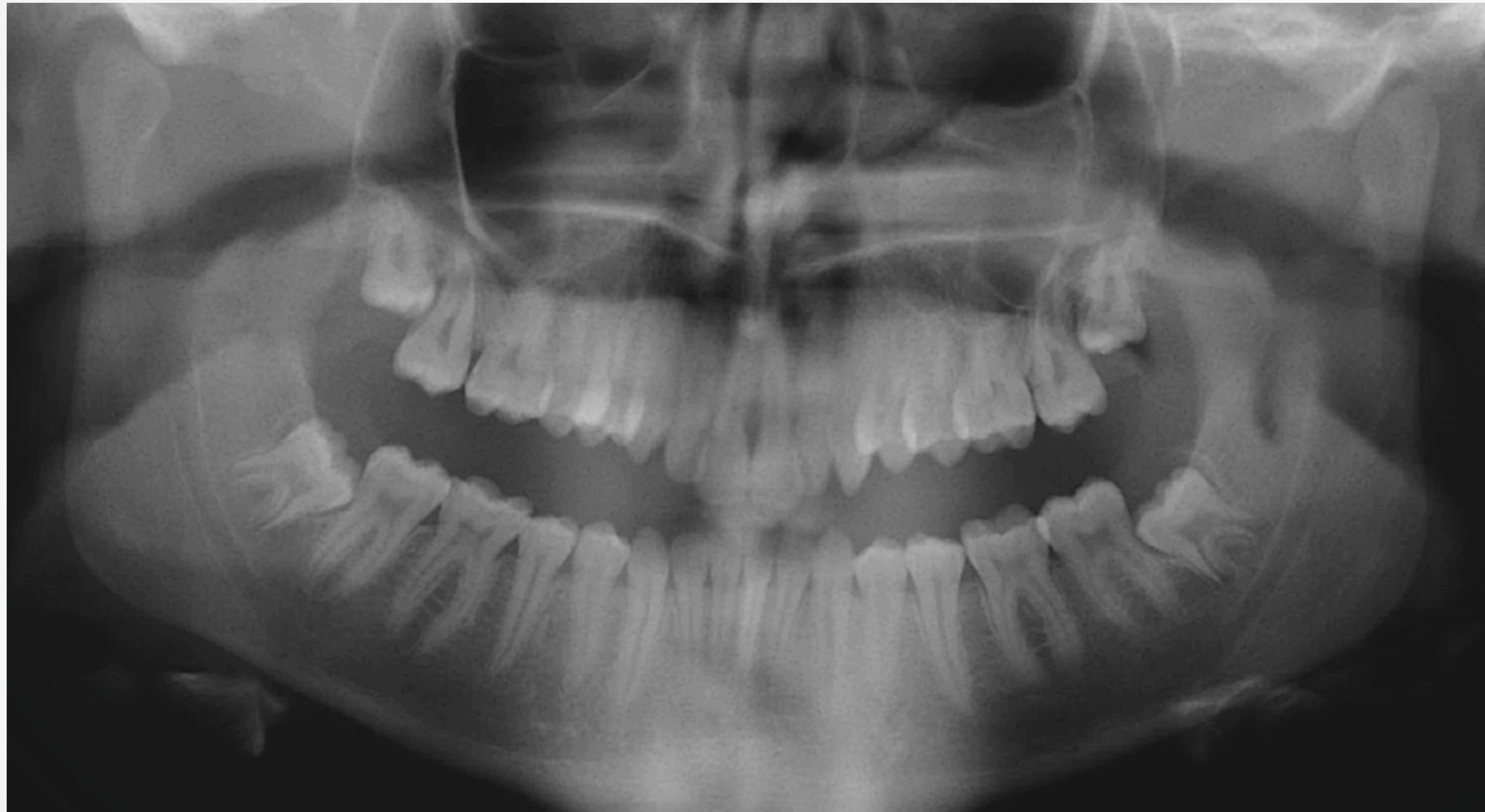Sample Case #9

Question 1



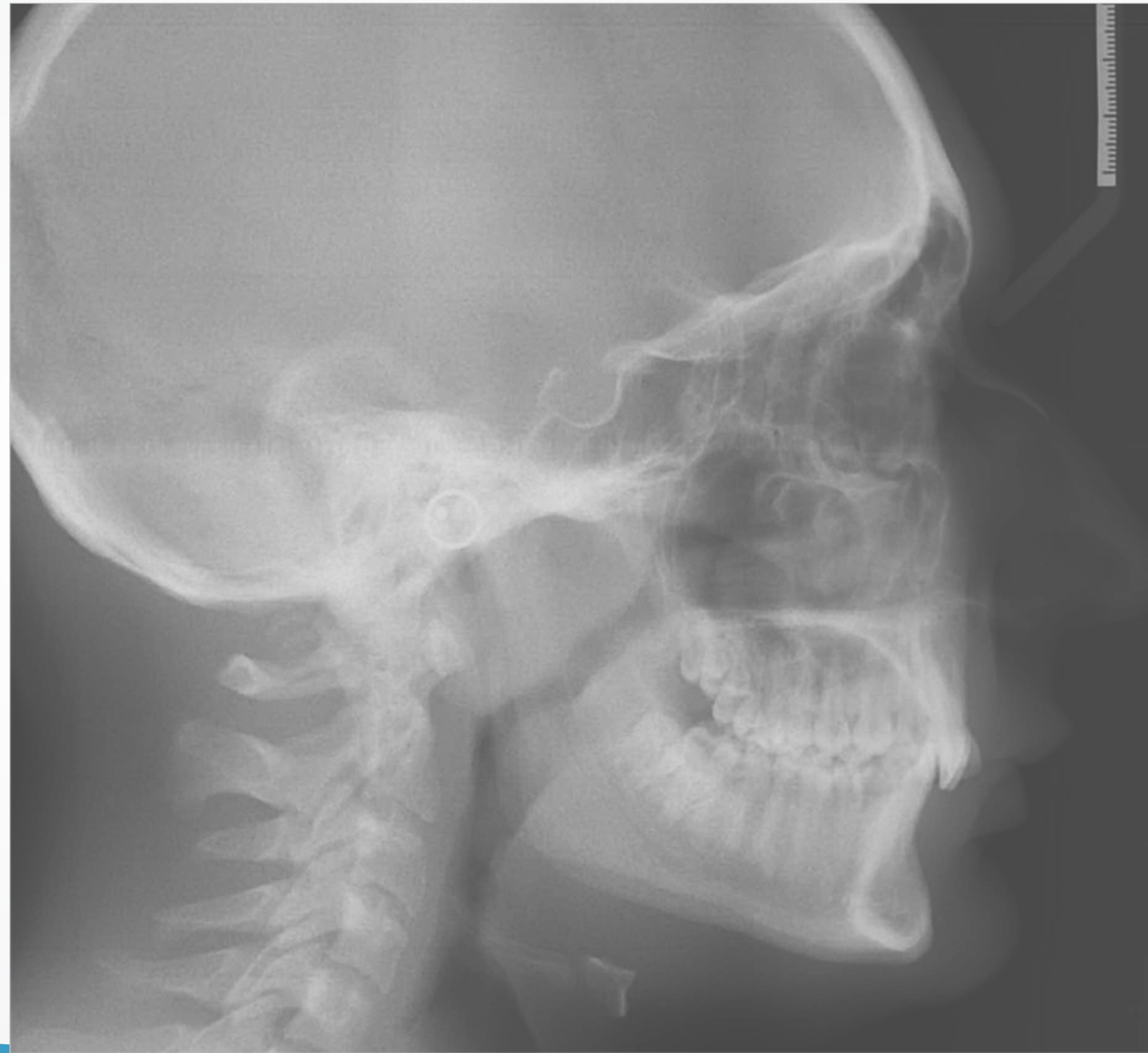Sample Case #9

Question 1



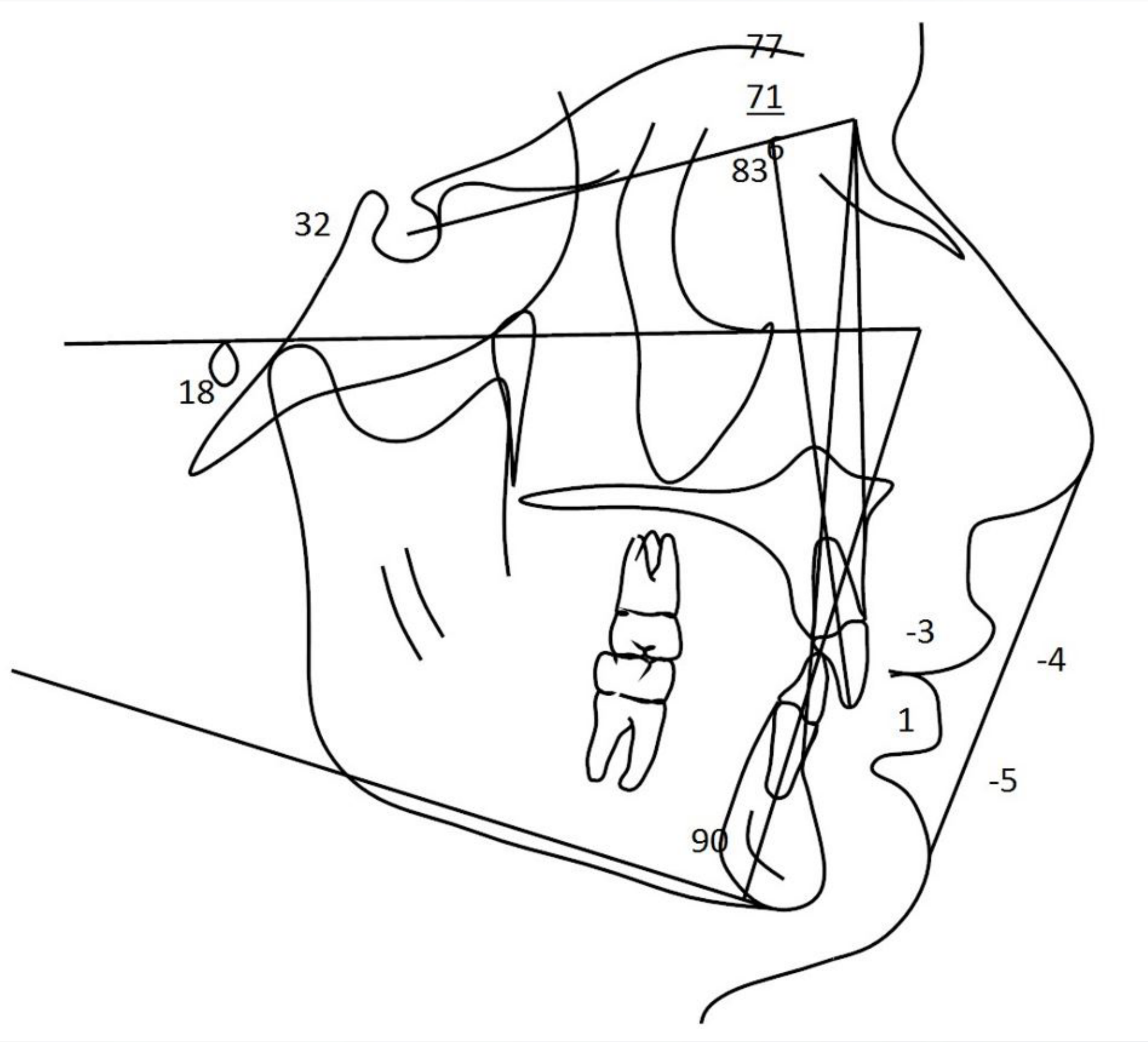
Sample Case #9

Question 1



Sample Case #9

Question 1



Sample Case #9

Question 1

Classification

Domain 1: Data Gathering and Diagnosis

Prompt

Provide a facial diagnosis for this patient. Please respond in numbered list format below.

Sample Case #9

Question 1

Fully Proficient Model Response

The examinee's response must include five or more of the following:

1. Convex profile
2. Obtuse nasolabial angle
3. Deep mentolabial sulcus
4. Prominent chin
5. Decreased lower anterior facial height
6. Retrusive lips relative to the E-line

Sample Case #9

Question 1

Borderline Proficient Model Response

The examinee's response must include four of the above.

Not Proficient Model Response

The examinee's response includes three or fewer of the above.

Sample Case #9

Question 2

Classification

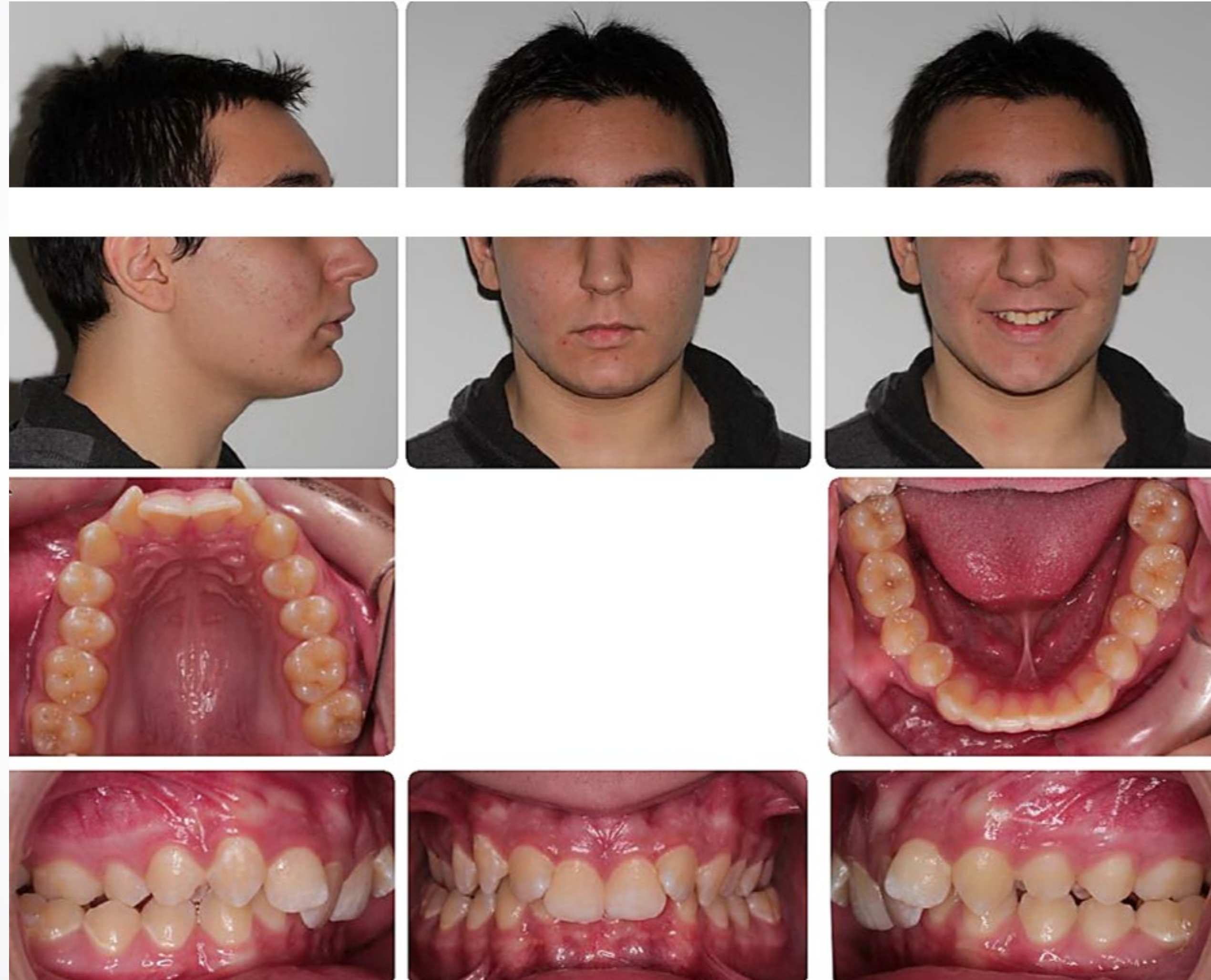Domain 2: Treatment Objectives and Planning

Prompt

Identify the dental findings for this patient. Please respond in numbered list format below.

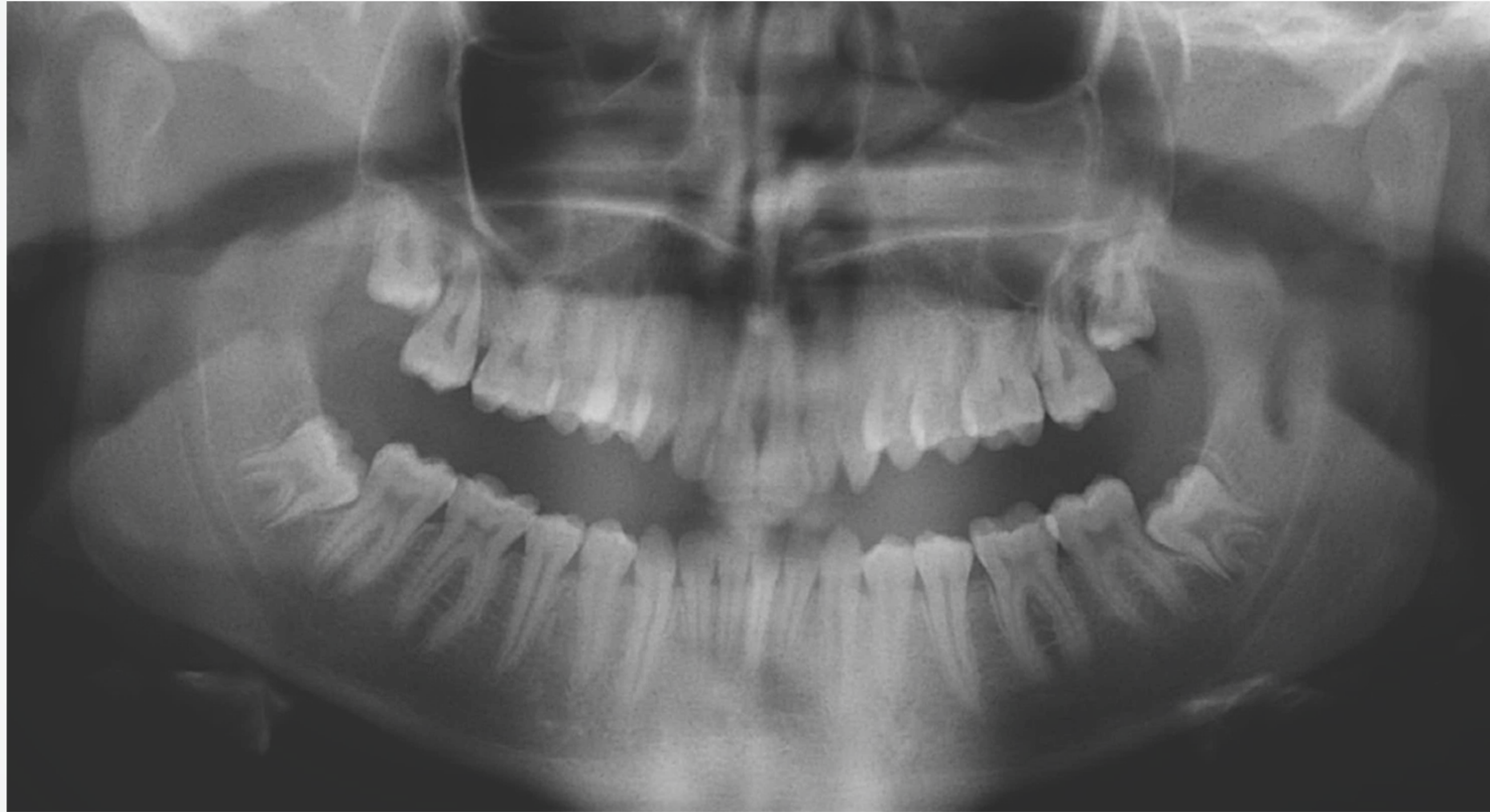
Sample Case #9

Question 2



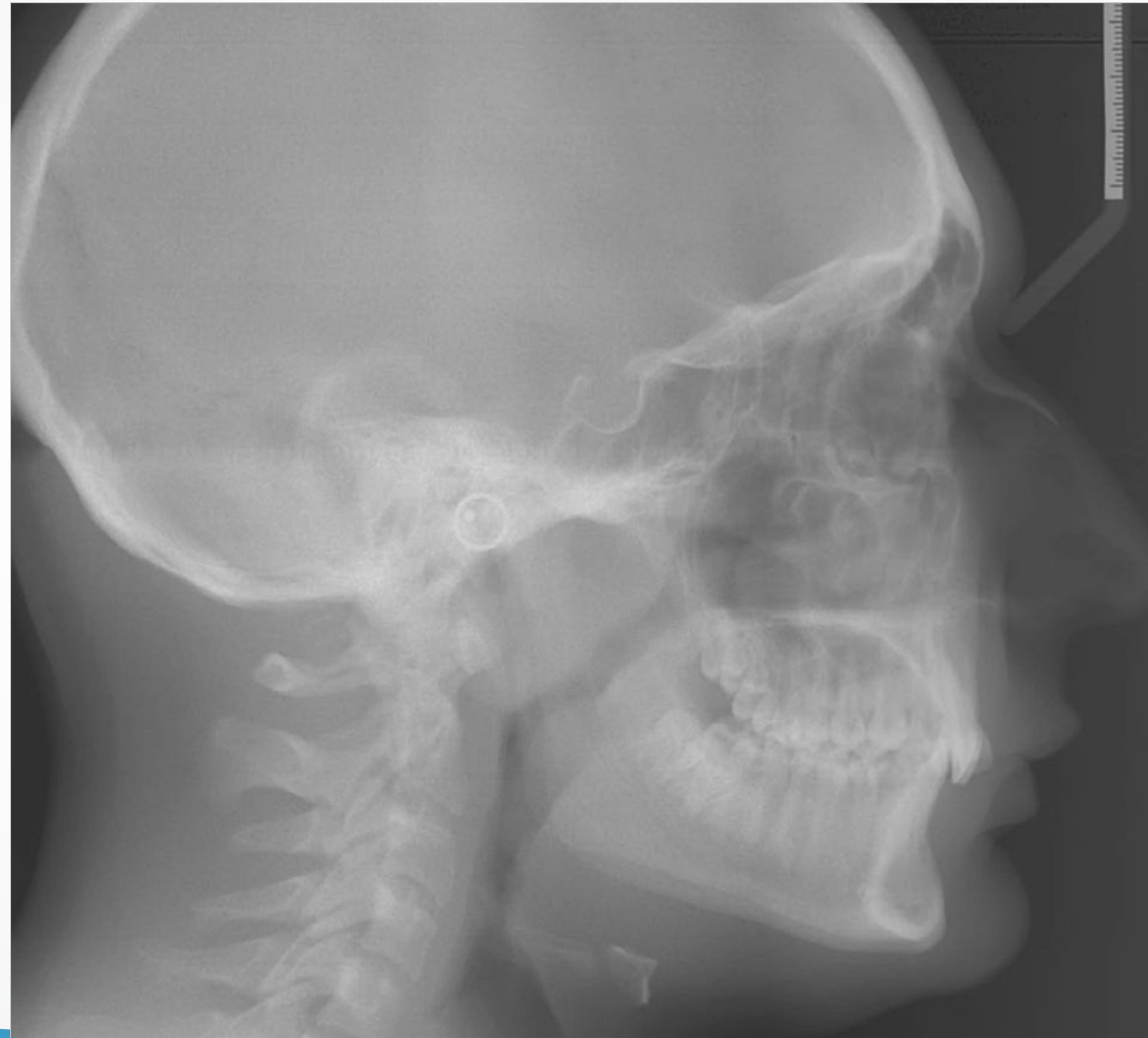Sample Case #9

Question 2



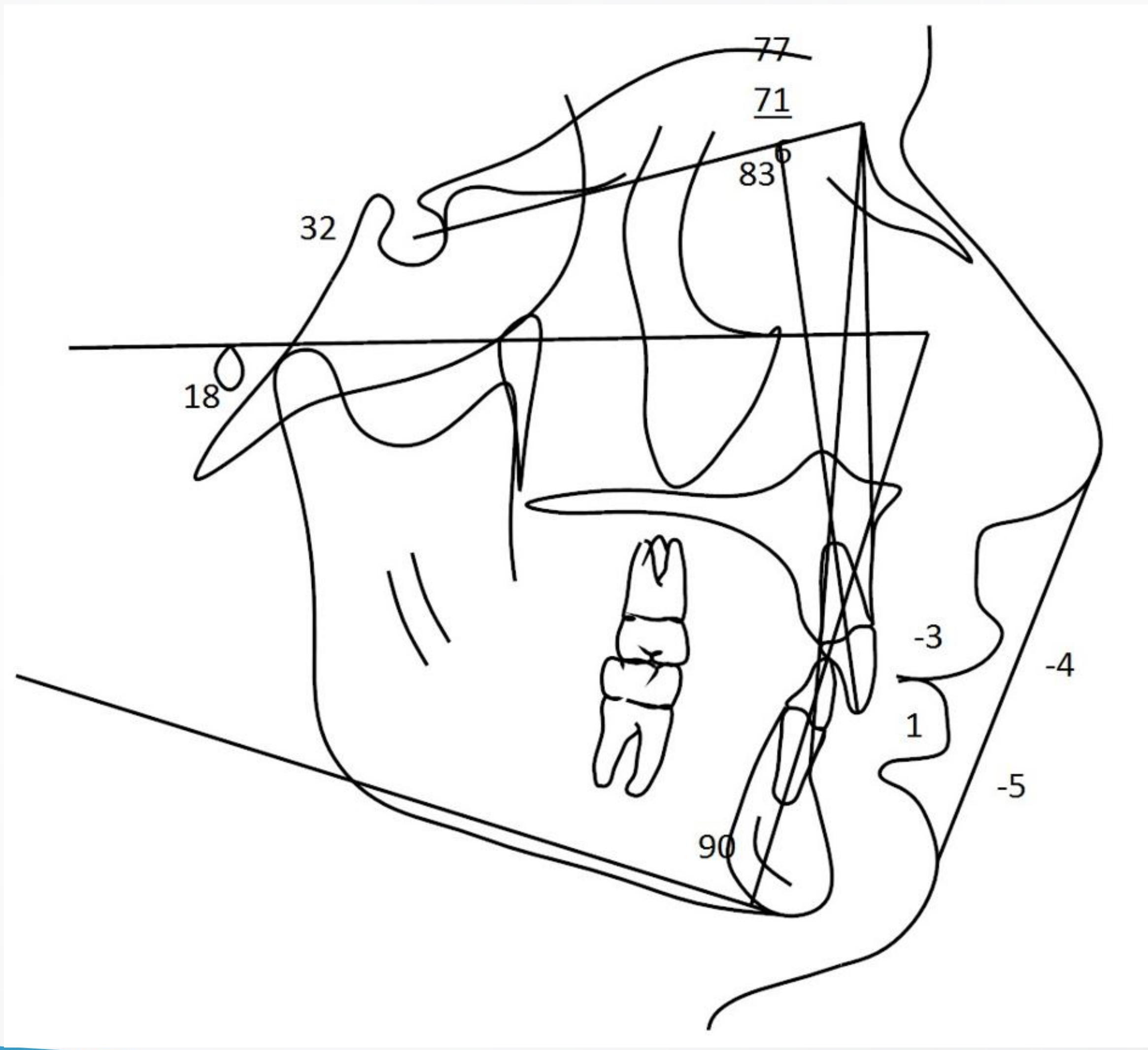
Sample Case #9

Question 2



Sample Case #9

Question 2



Sample Case #9

Question 2

Classification

Domain 2: Treatment Objectives and Planning

Prompt

Identify the dental findings for this patient. Please respond in numbered list format below.

Sample Case #9

Question 2

Fully Proficient Model Response

The examinee's response must include eight or more of the following:

1. Class II molar relationship
2. Deep overbite (or impinging)
3. Deep curve of Spee
4. Maxillary reverse curve of Spee (or supraeruption of maxillary incisors)
5. Bilateral posterior crossbite
6. Mandibular crowding
7. Maxillary crowding
8. Rotations
9. Retroclined (or uprighted) maxillary central incisors
10. Impacted third molars

Sample Case #9

Question 2

Borderline Proficient Model Response

The examinee's response must include seven of the above.

Not Proficient Model Response

The examinee's response includes six or fewer of the above.

Sample Case #9

Question 3

Classification

Domain 2: Treatment Objectives and Planning

Prompt

List the key components of an orthognathic surgical treatment plan for this patient. Please respond in numbered list format below.

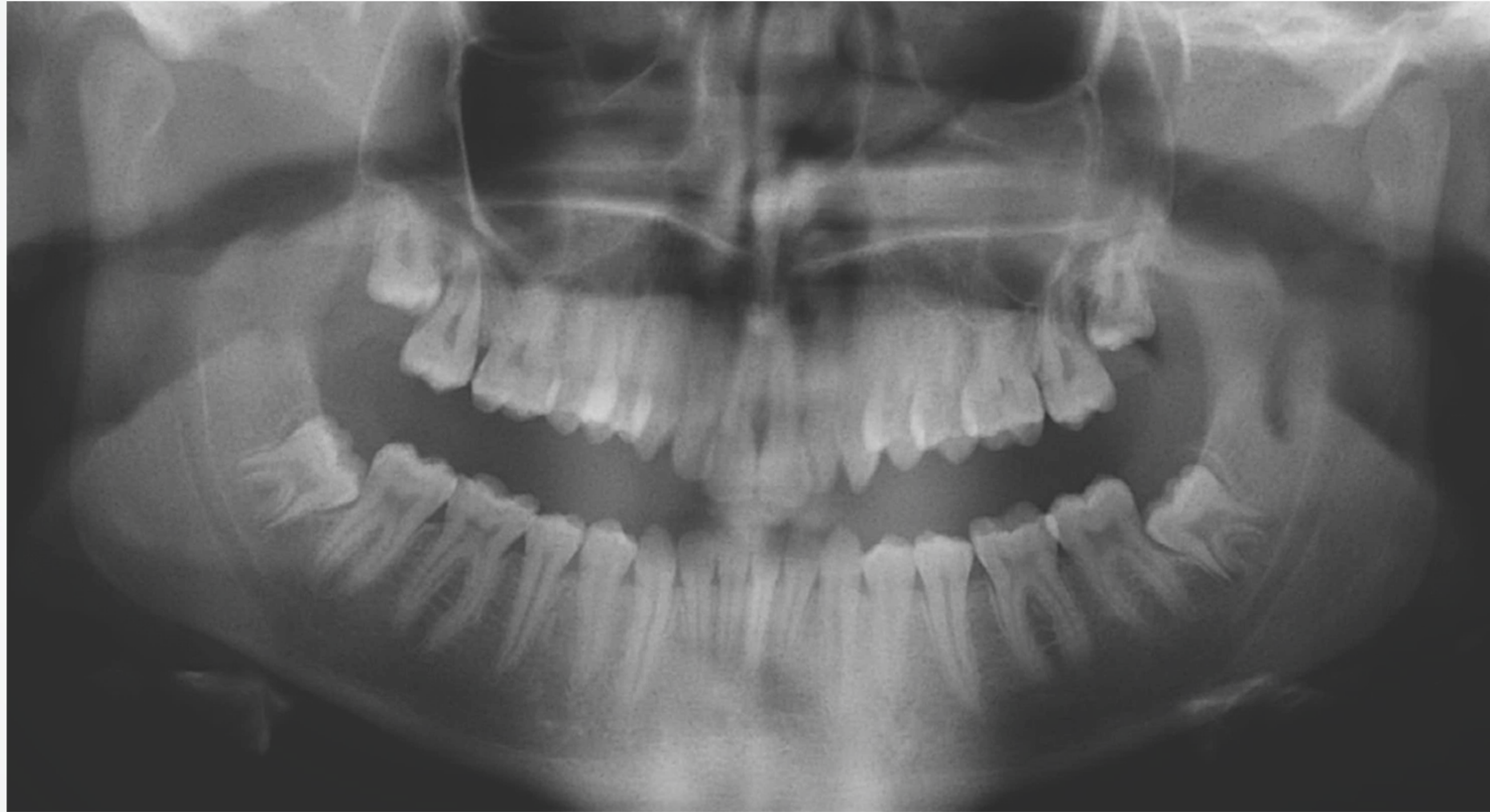
Sample Case #9

Question 3



Sample Case #9

Question 3



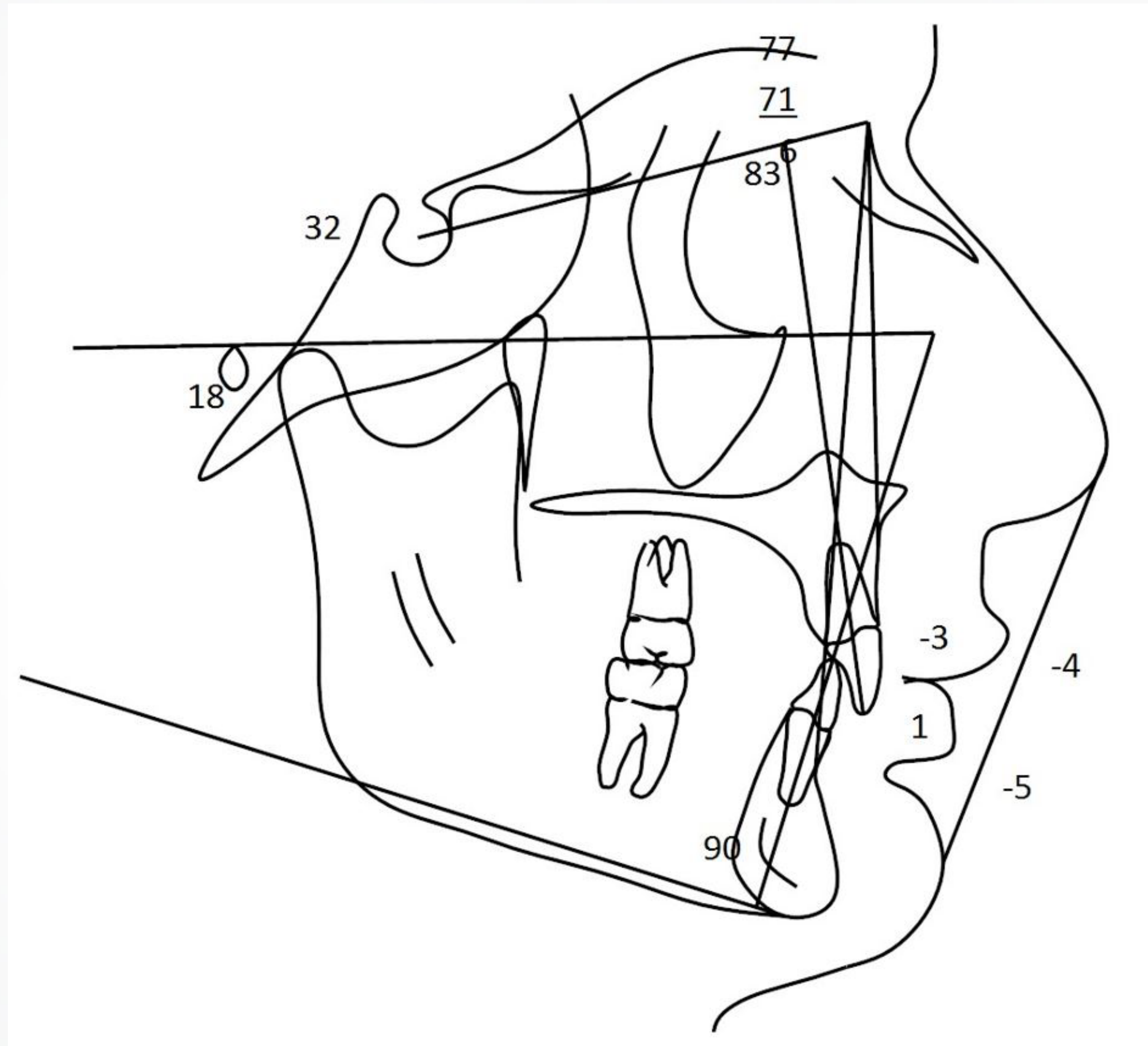
Sample Case #9

Question 3



Sample Case #9

Question 3



Sample Case #9

Question 3

Classification

Domain 2: Treatment Objectives and Planning

Prompt

List the key components of an orthognathic surgical treatment plan for this patient. Please respond in numbered list format below.

Sample Case #9

Question 3

Fully Proficient Model Response

The examinee's response must include:

- Mandibular advancement (accept BSSO with advancement)

And five or more additional responses from the following:

1. Extract third molars
2. Level and align maxillary arch
3. Align mandibular arch
4. Maintain the mandibular curve of Spee presurgically
5. Presurgical arch coordination
6. Palatal expansion (MARPE, SARPE, or segmental osteotomy)
7. Postsurgical leveling of the curve of Spee

Sample Case #9

Question 3

Borderline Proficient Model Response

The examinee's response must include:

- Mandibular advancement (accept BSSO with advancement)

And four additional responses from the above:

Not Proficient Model Response

The examinee's response fails to include:

- Mandibular advancement (accept BSSO with advancement)

Or includes mandibular advancement, but includes three or fewer of the above:



Sample Case #10

Sample Case #10

Opening Scenario:

A 18-year-old female presents with the chief complaint that “my teeth stick out.”

Sample Case #10

Question 1

Classification

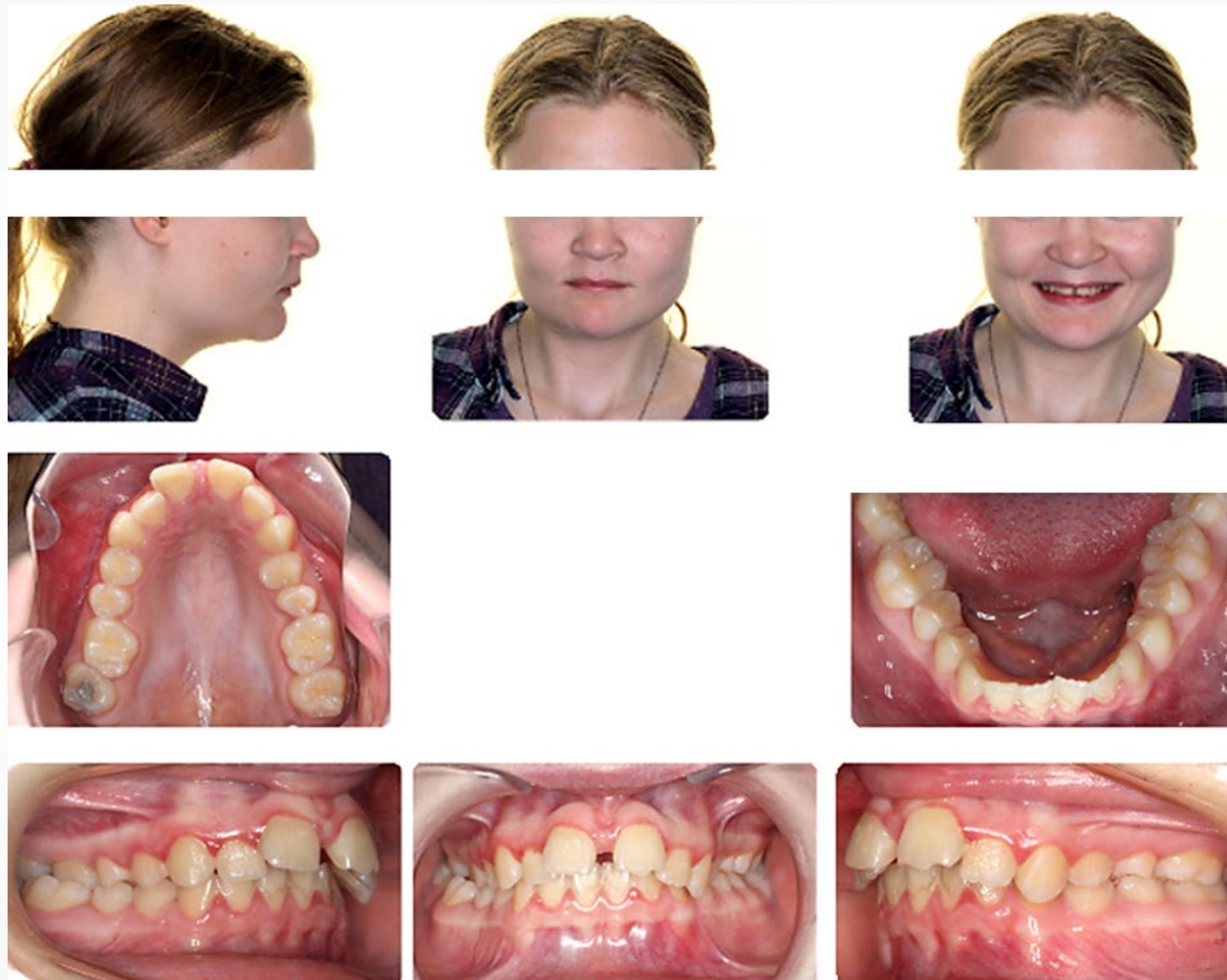Domain 1: Data Gathering and Diagnosis

Prompt

Identify the skeletal abnormalities for this patient. Please respond in numbered list format below.

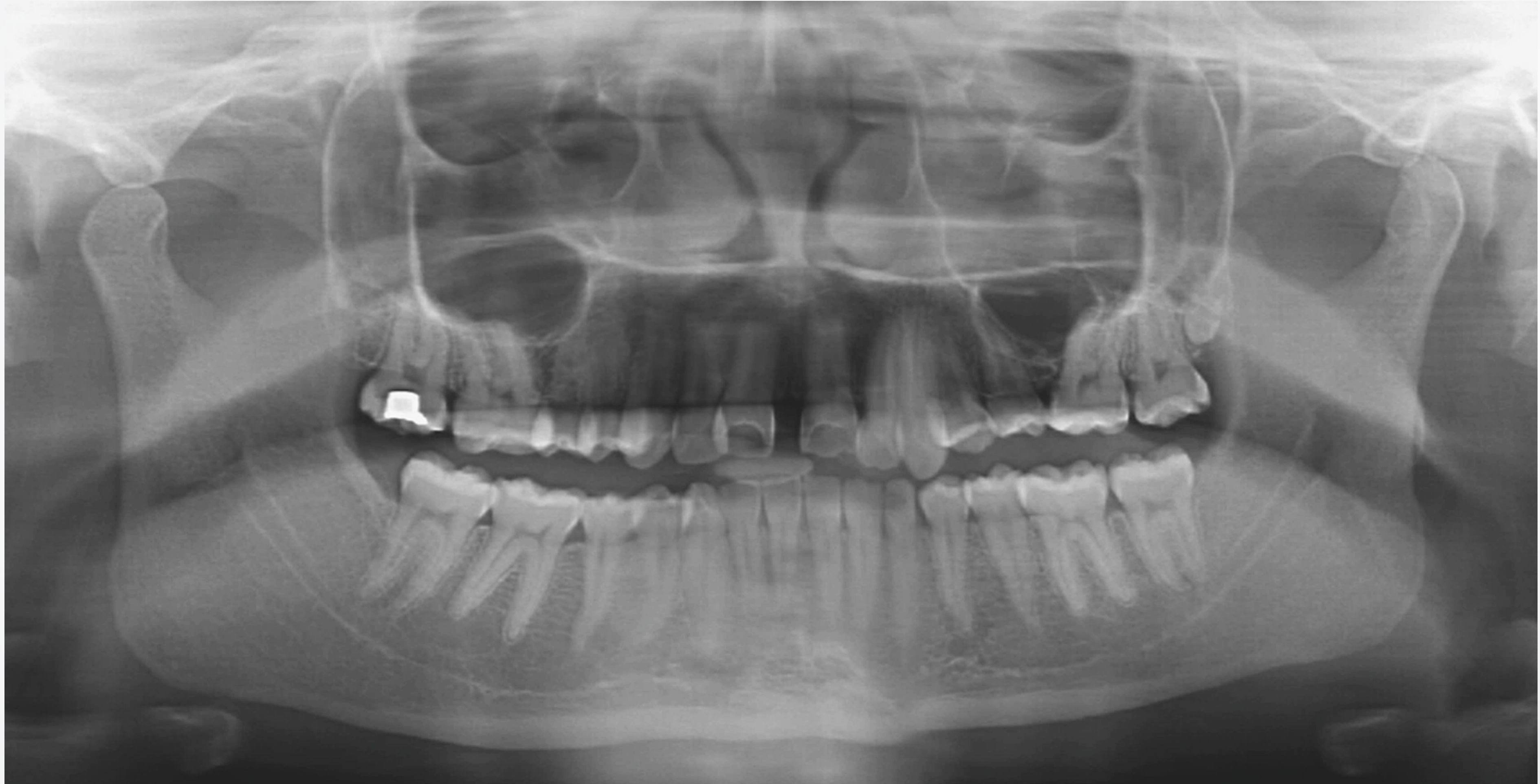
Sample Case #10

Question 1



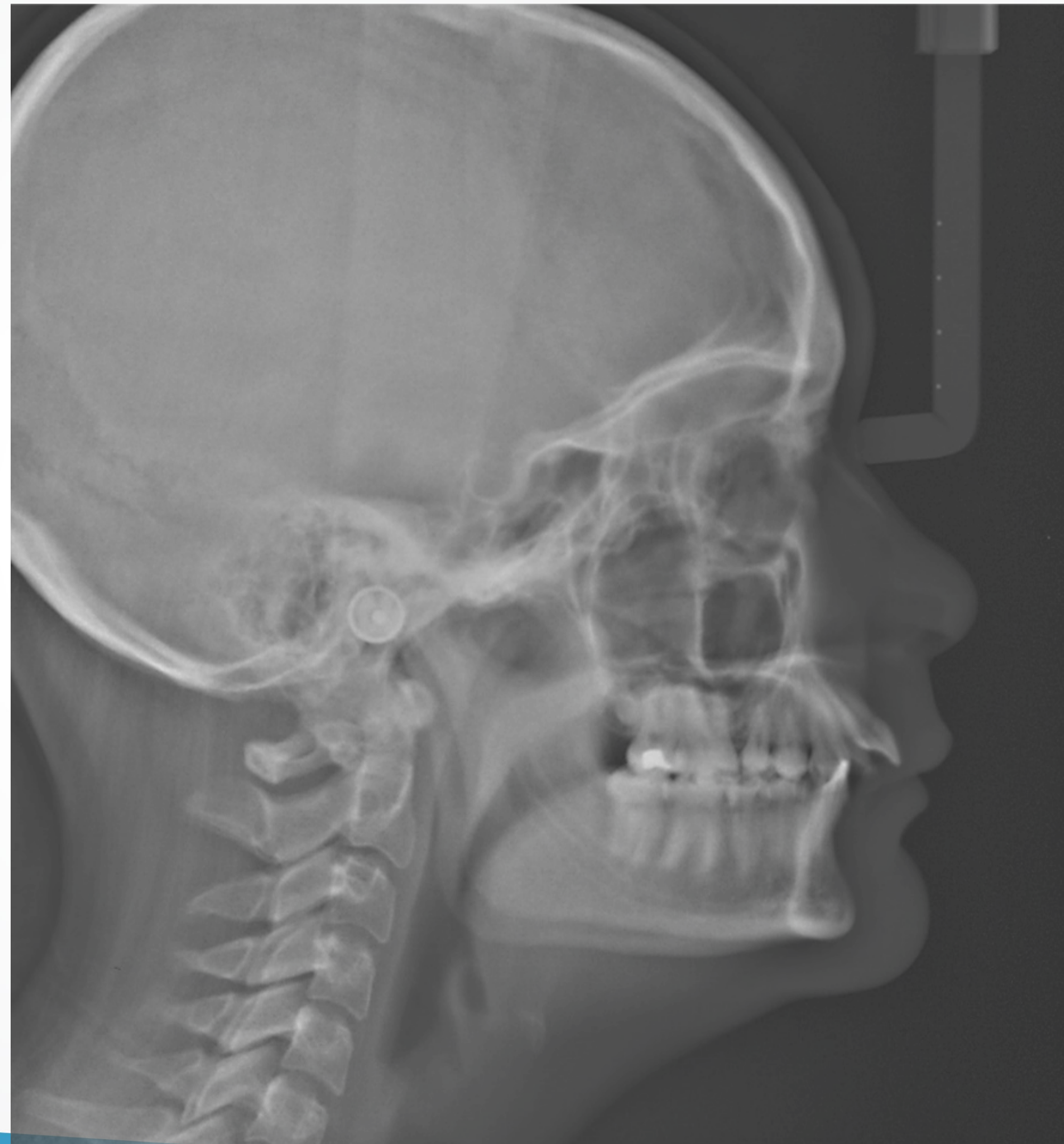Sample Case #10

Question 1



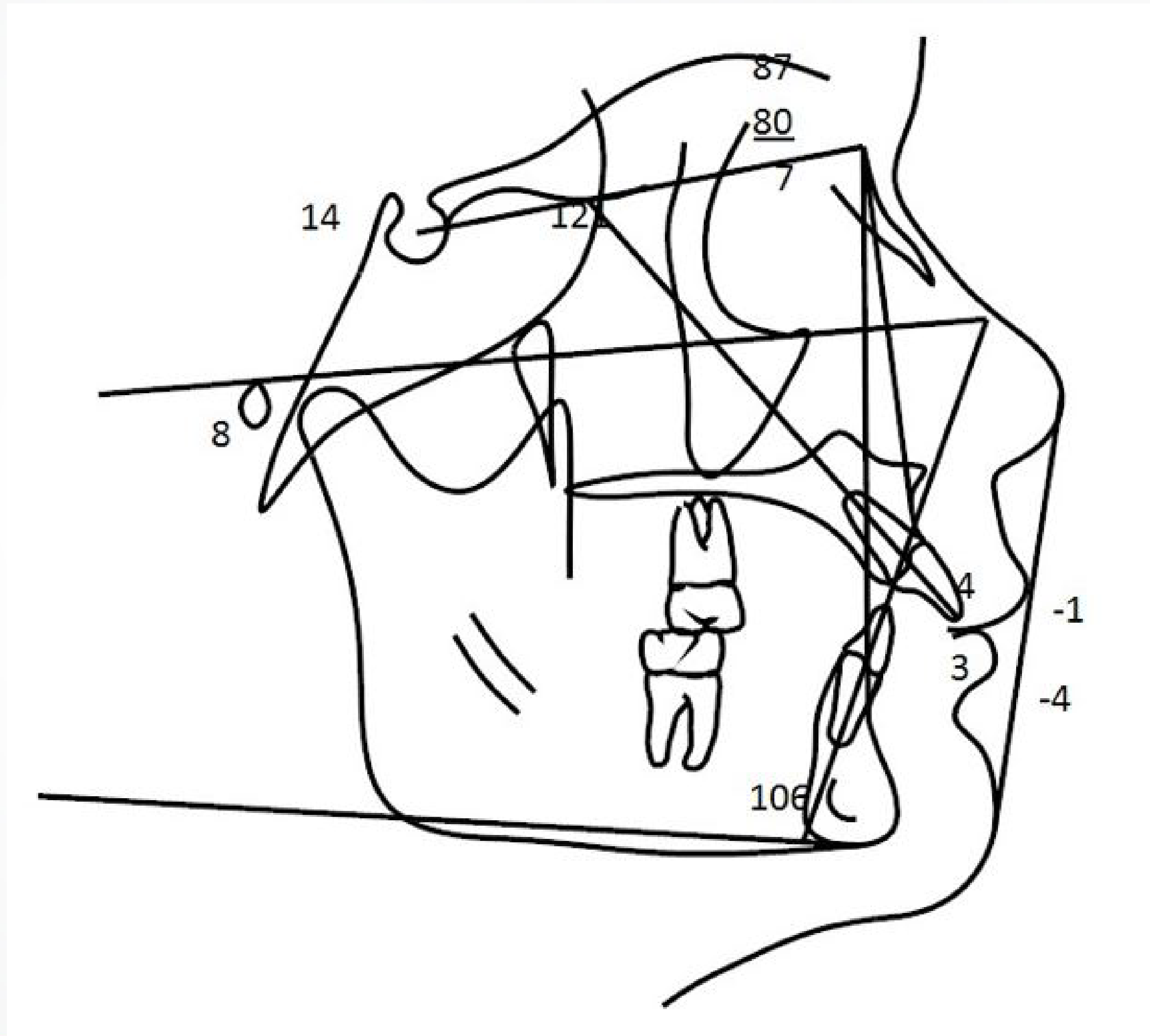
Sample Case #10

Question 1



Sample Case #10

Question 1



Sample Case #10

Question 1

Classification

Domain 1: Data Gathering and Diagnosis

Prompt

Identify the skeletal abnormalities for this patient. Please respond in numbered list format below.

Sample Case #10

Question 1

Fully Proficient Model Response

The examinee's response must include five or more of the following:

1. Excessive skeletal convexity (or ANB=6 or skeletal Class II)
2. Hypodivergent (or extremely low mandibular plane angle)
3. Retrusive mandible
4. Constricted maxilla
5. Decreased lower anterior facial height
6. Increased posterior facial height

Sample Case #10

Question 1

Borderline Proficient Model Response

The examinee's response must include four of the above.

Not Proficient Model Response

The examinee's response includes three or fewer of the above.

Sample Case #10

Question 2

Classification

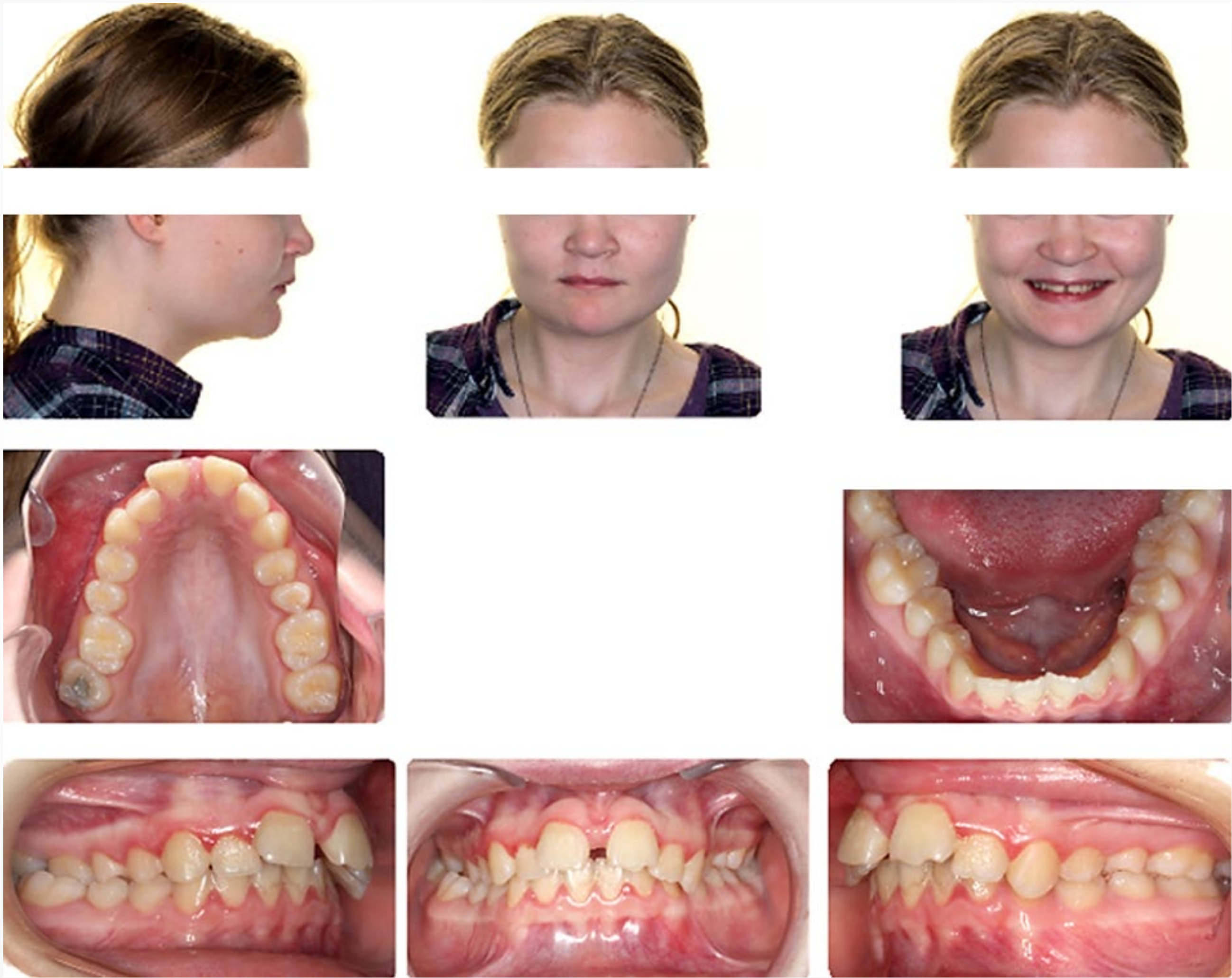Domain 1: Data Gathering and Diagnosis

Prompt

List the dental problems for this patient. Please respond in numbered list format below.

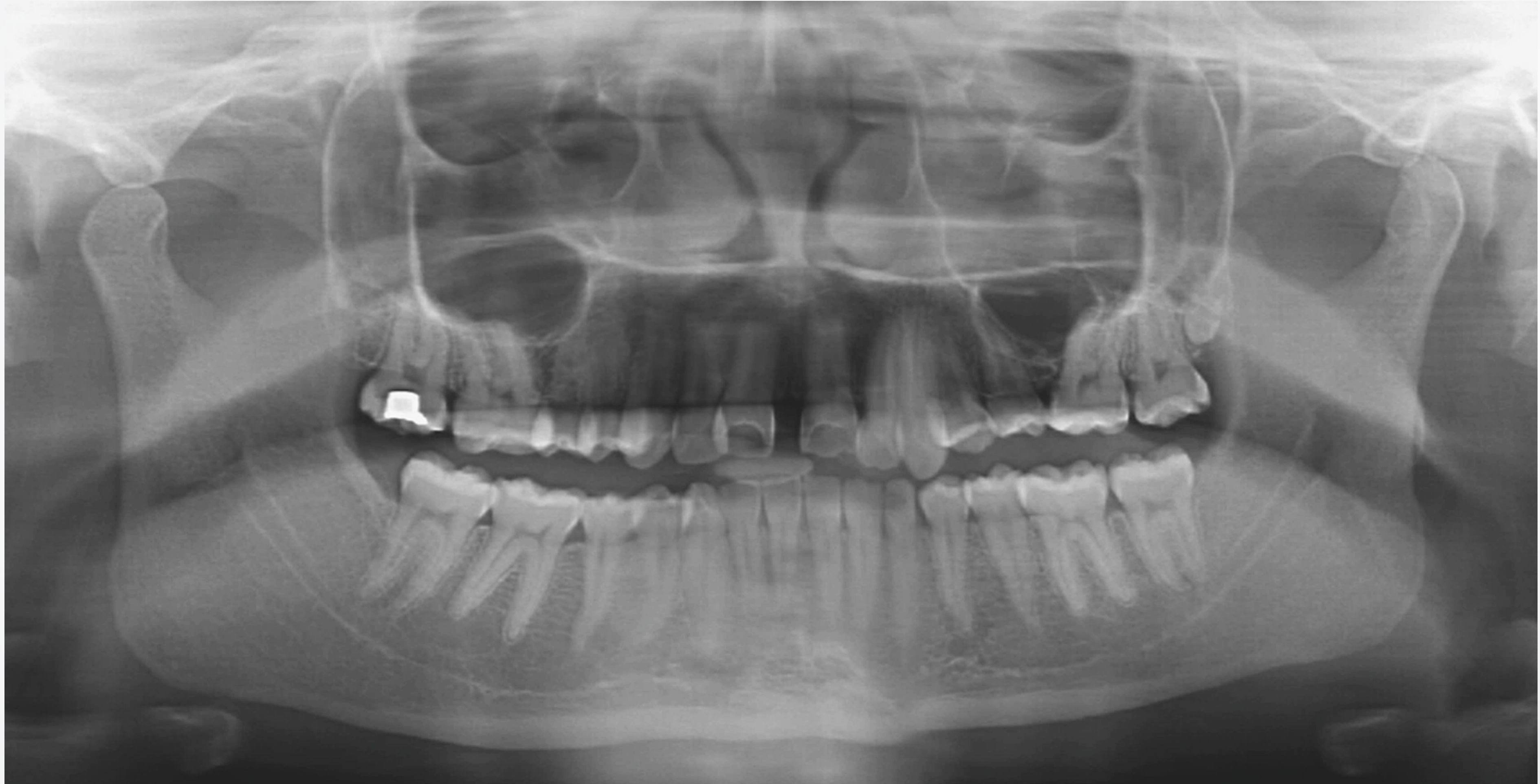
Sample Case #10

Question 2



Sample Case #10

Question 2



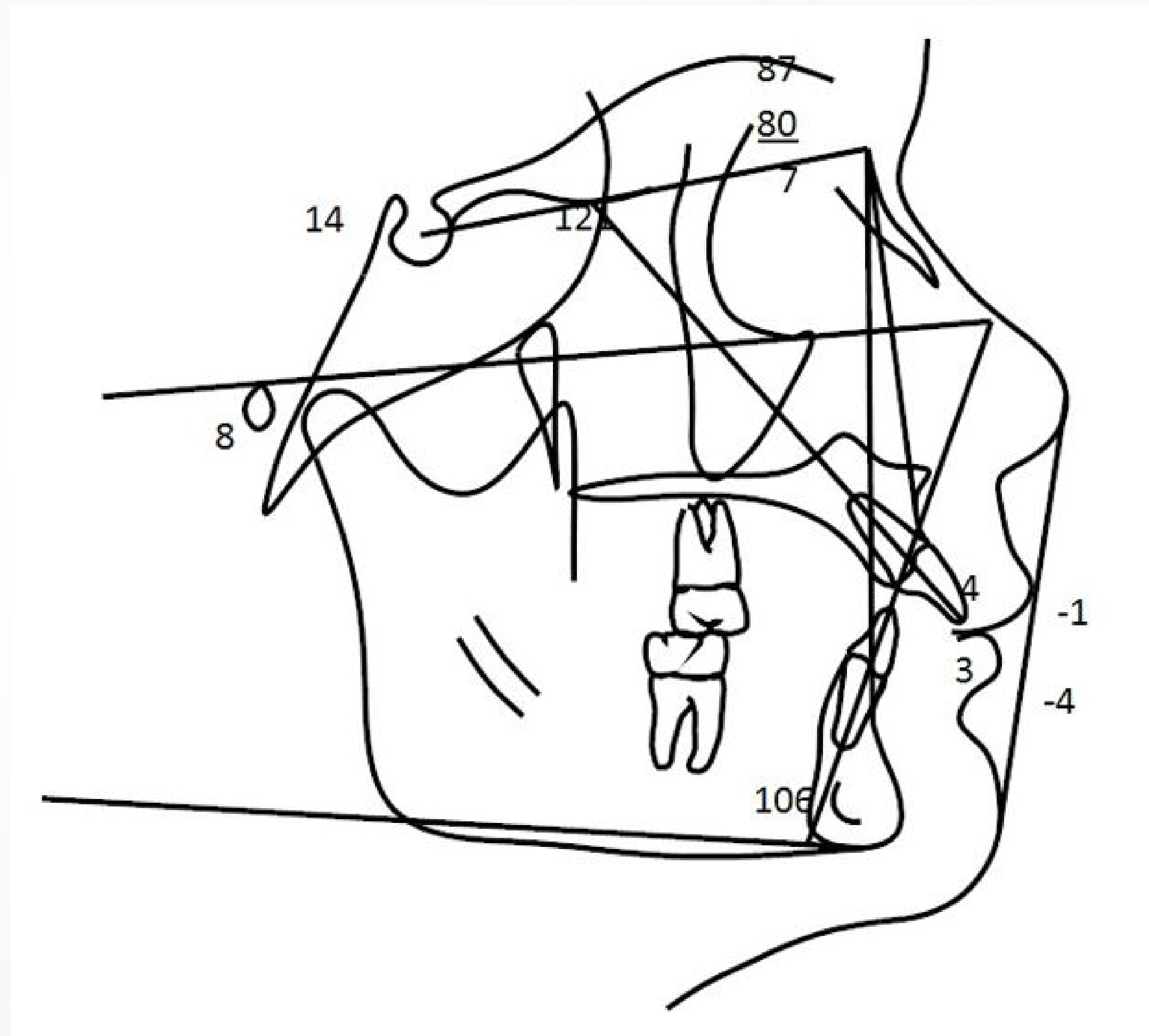
Sample Case #10

Question 2



Sample Case #10

Question 2



Sample Case #10

Question 2

Classification

Domain 1: Data Gathering and Diagnosis

Prompt

List the dental problems for this patient. Please respond in numbered list format below.

Sample Case #10

Question 2

Fully Proficient Model Response

The examinee's response must include seven or more of the following:

1. Class II molar relationship
2. Proclined maxillary incisors
3. Excessive overjet
4. Impinging deep overbite
5. Deep curve of Spee
6. Right posterior crossbite
7. Mandibular crowding
8. Maxillary midline diastema
9. Thick labial frenum (accept low frenum)

Sample Case #10

Question 2

Borderline Proficient Model Response

The examinee's response must include six of the above.

Not Proficient Model Response

The examinee's response includes five or fewer of the above.

Sample Case #10

Question 3

Classification

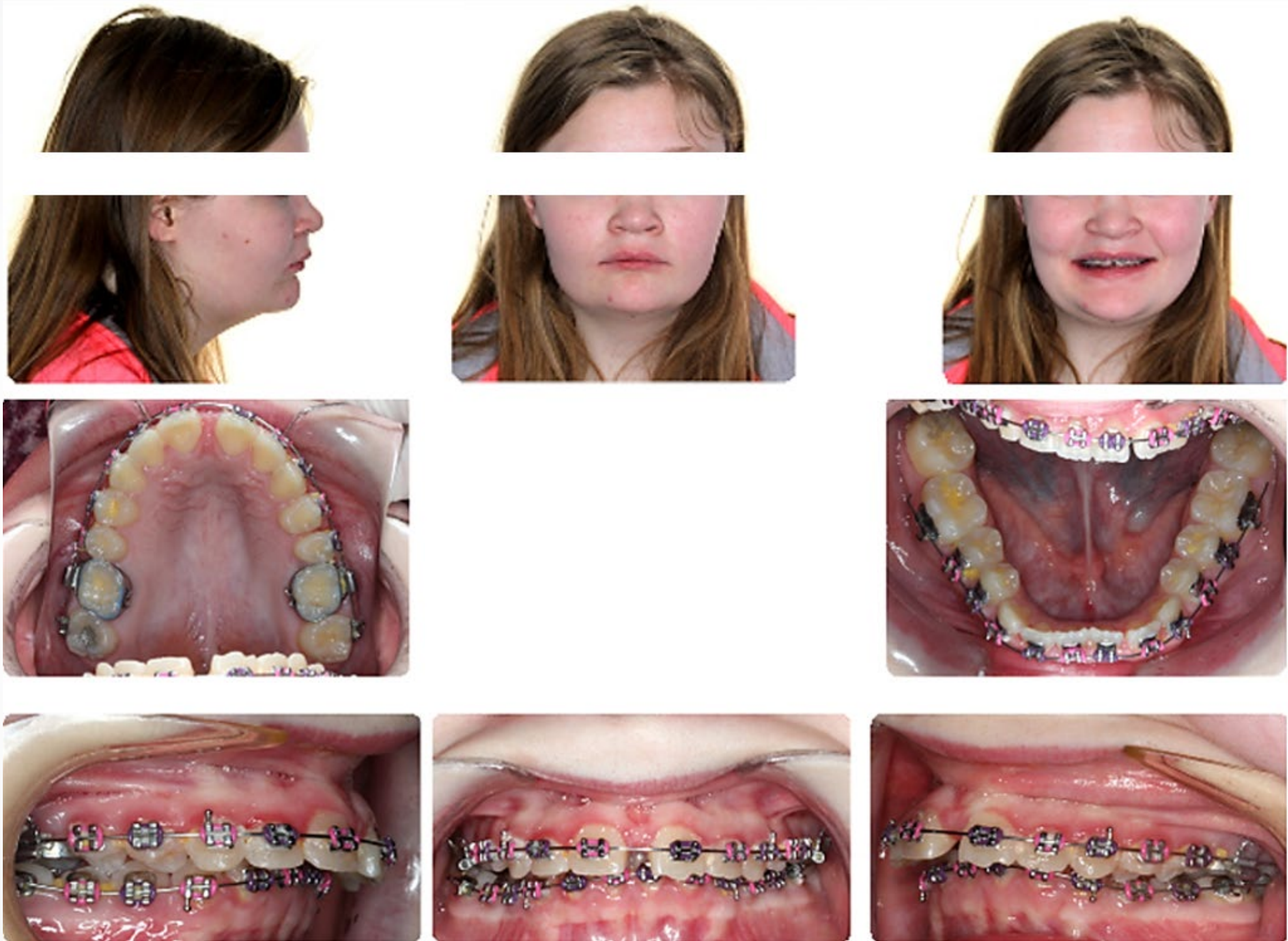Domain 3: Treatment Implementation and Management

Prompt

List treatment steps to prepare this patient for orthognathic surgery.
Please respond in numbered list format below.

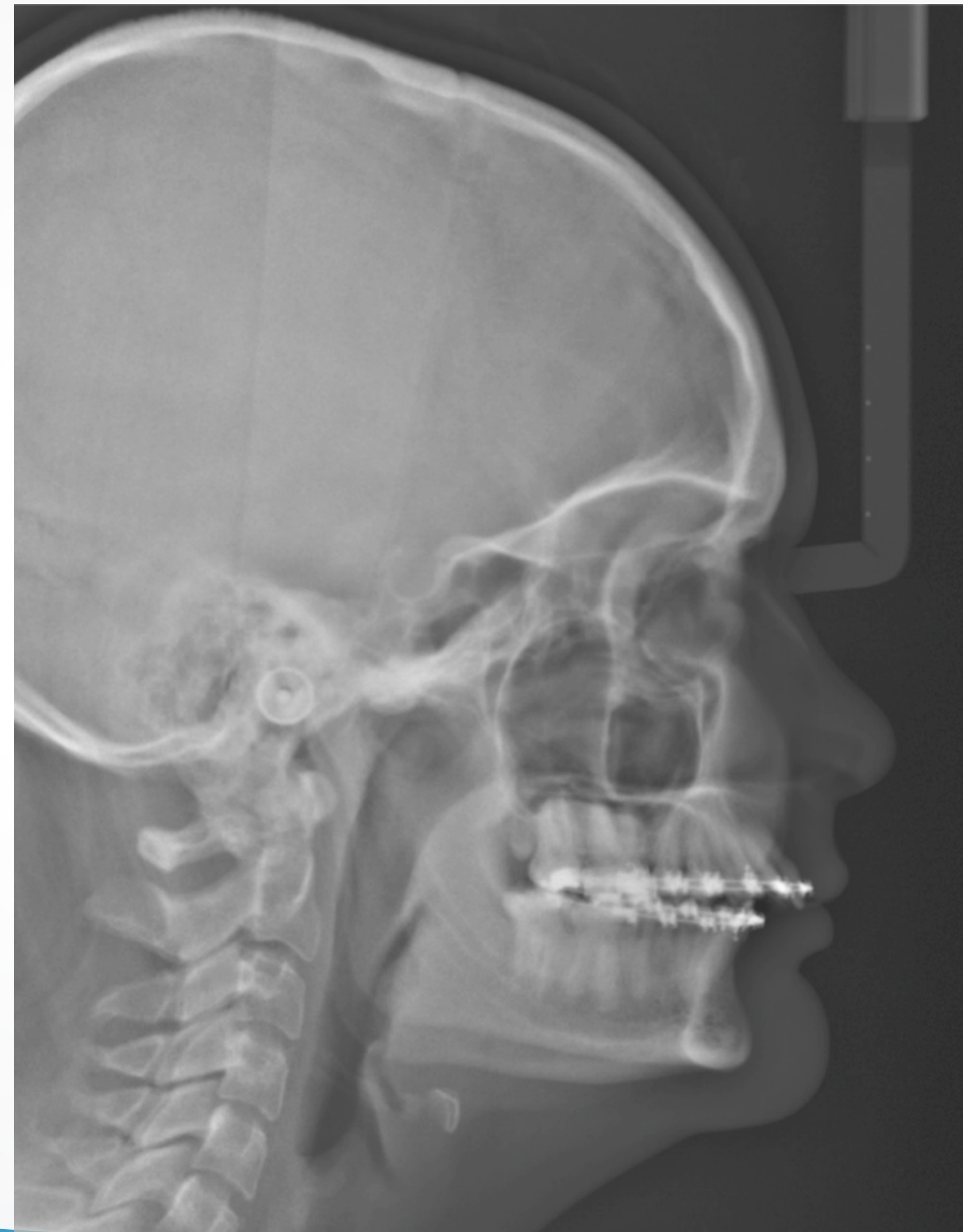Sample Case #10

Question 3



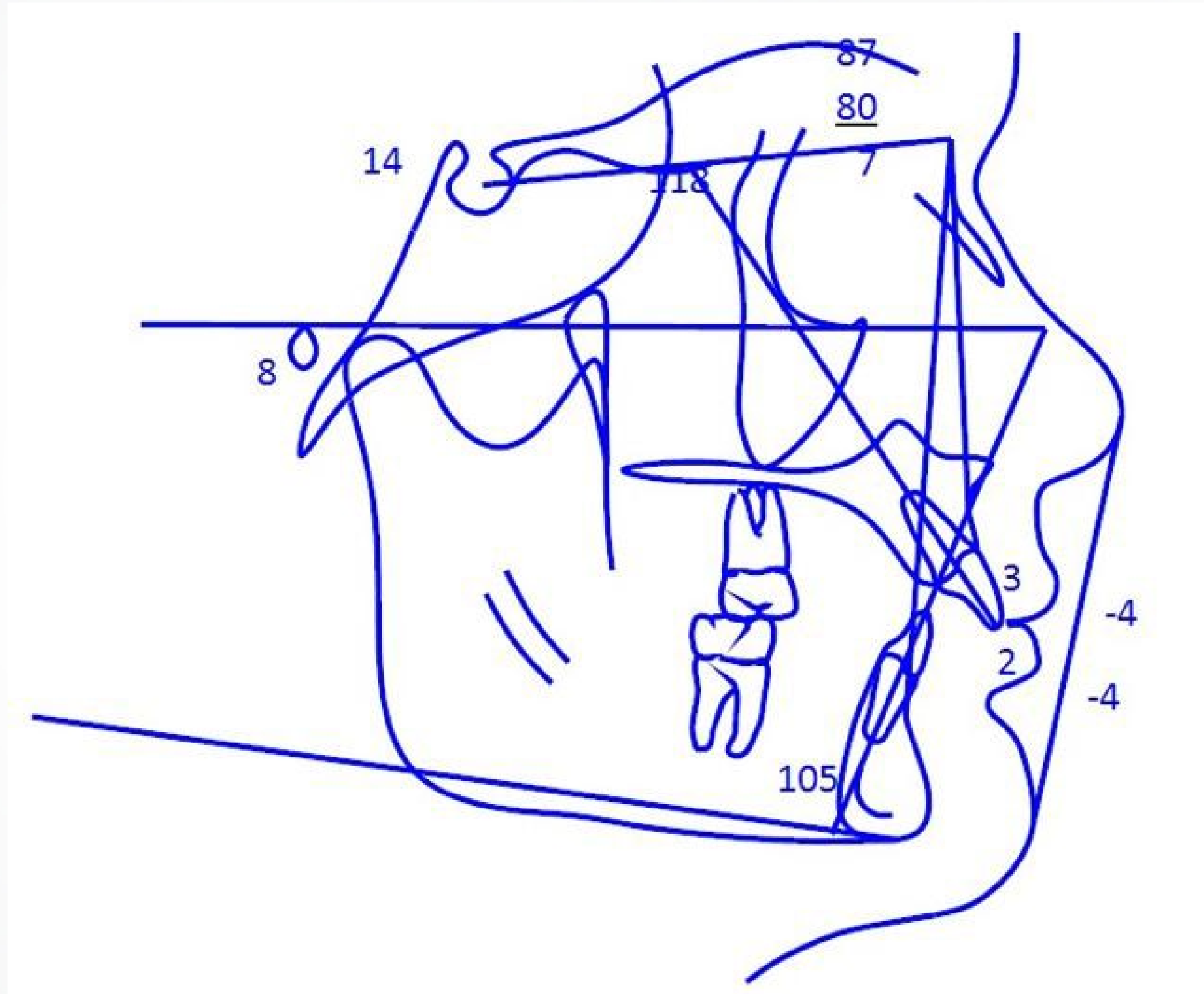
Sample Case #10

Question 3



Sample Case #10

Question 3



Sample Case #10

Question 3

Classification

Domain 3: Treatment Implementation and Management

Prompt

List treatment steps to prepare this patient for orthognathic surgery.
Please respond in numbered list format below.

Sample Case #10

Question 3

Fully Proficient Model Response

The examinee's response must include five or more of the following:

1. Oral hygiene improvement
2. Band or bond mandibular second molars
3. Space closure
4. Retrocline maxillary incisors
5. Coordinate arches
6. Maintain curve of Spee prior to surgery

Sample Case #10

Question 3

Borderline Proficient Model Response

The examinee's response must include four of the above.

Not Proficient Model Response

The examinee's response includes three or fewer of the above.